

course, the chairman of the committee's panel reviewing the autopsy. It would be appropriate now, Mr. Chairman, to call Dr. Baden.

Chairman STOKES. The committee calls Dr. Baden.

Dr. Baden, would you raise your right hand, please?

Do you solemnly swear the testimony you will give before this committee is the truth, the whole truth, and nothing but the truth, so help you God?

Dr. BADEN. I do.

Chairman STOKES. Thank you. You may be seated.

Before I recognize counsel. Dr. Baden, I understand you will be giving testimony relative to illustrated photographs.

**TESTIMONY OF DR. MICHAEL BADEN, PATHOLOGIST AND
CHIEF MEDICAL EXAMINER FOR THE CITY OF NEW YORK**

Dr. BADEN. Taken at the autopsy, yes, sir.

Chairman STOKES. I guess it is important at this point that the record reflect the fact that the photographs which are sealed in the National Archives have been made available to the appropriate members of this committee staff and to the members of this committee.

The committee has viewed those photographs as late as this past evening. The committee feels it would be in extremely poor taste for this committee to submit those photographs to public view. It also, in our opinion, would be an invasion of the privacy of the President's family. It is for that reason that these photographs will remain sealed and will not be displayed during the course of these hearings.

The committee, at this time, will recognize counsel Kenneth Klein.

Mr. KLEIN. Thank you, Mr. Chairman.

Doctor, what is your current position?

Dr. BADEN. I am Chief Medical Examiner of the City of New York.

Mr. KLEIN. What are your duties as chief medical examiner of the city of New York?

Dr. BADEN. My duties include supervision and responsibility for the functioning of the Office of Chief Medical Examiner of New York City, which has responsibility to investigate all sudden, suspicious, and unnatural deaths that occur in the five boroughs of New York City.

Mr. KLEIN. During the course of your duties as Chief Medical Examiner, do you perform autopsies?

Dr. BADEN. Yes, sir.

Mr. KLEIN. What is an autopsy?

Dr. BADEN. An autopsy is a systematic external and internal examination of the dead body to determine any abnormalities that might be present to assist in determining cause of death.

Mr. KLEIN. What is your specialty as a medical doctor?

Dr. BADEN. My specialty is pathology and within that area, forensic pathology.

Mr. KLEIN. What is forensic pathology?

Dr. BADEN. Pathology is that area of medicine concerned with the investigation and evaluation of natural disease and other abnormalities in the human body; and forensic pathology specifically

refers and relates to investigation of unnatural death and to areas of pathology and medicine that are concerned with legal aspects of death and injury, and ability to present these materials in courts and other jurisdictions.

Mr. KLEIN. Prior to serving on the panel, did you have any contact with the Kennedy case?

Dr. BADEN. No, I had not.

Mr. KLEIN. Mr. Chairman, I would ask that this document marked JFK F-19 be received as a committee exhibit and shown to the witness.

Chairman STOKES. Without objection, it may be received as a committee exhibit and entered into the record at this point.

[The above-referred-to exhibit, JFK F-19, follows:]

JFK EXHIBIT F-19

LISTING OF MATERIALS PROVIDED TO THE PATHOLOGY PANEL BY
THE SELECT COMMITTEE - JOHN F. KENNEDY1. AUTOPSY AND RELATED MATERIALS

Autopsy Protocol 11-22-63
 Supplementary Autopsy Report 12-6-63
 Notes of Dr. James J. Humes 11-23-63
 Autopsy Descriptive Sheet 11-22-63
 Death Certificate 11-22-63
 Authorization for Post-Mortem Examination 11-22-63
 Report of Inquest 12-6-63
 Original autopsy photographs
 Original autopsy X-rays
 Comparison X-rays 1960-63
 Clothing worn at time of assassination
 LogeTronic X-ray enhancements of original X-rays
 Aerospace Corporation computer enhancements of original
 X-rays and photographs
 1966 Index by Drs. Humes, Boswell, Ebersole and Stringer
 1967 Report by Drs. Humes, Boswell and Finck
 Dr. Finck's notes
 Dr. Finck's 1965 report
 Dr. Finck's 1967 Review
 Dr. Finck's Testimony - State of Louisiana v. Clay L. Shaw

2. WARREN COMMISSION TESTIMONY

Dr. James J. Humes
 Dr. Pierre A. Finck
 Dr. Thornton Boswell
 Dr. Malcolm O. Perry
 Dr. Martin G. White
 Dr. Paul C. Peters
 Dr. Adolph A. Giesecke, Jr.
 Dr. William K. Clark
 Dr. Don T. Curtis
 Dr. Fuoad A. Bashour
 Dr. Gene C. Atkin
 Dr. Charles J. Carrico
 Dr. Charles R. Baxter
 Rufus W. Youngblood
 Clinton Hill
 Roy H. Kellerman
 William Greer

Listing of Materials Provided to the Pathology Panel by
The Select Committee - John F. Kennedy

3. STAFF INTERVIEWS

Dr. Norman Chase
Dr. William Seaman
Dr. Malcolm O. Perry
Dr. C. James Carrico
Dr. Marion T. Jenkins
Admiral George Burkley, M.D.
Dr. John Lattimer

4. BALLISTICS MATERIALS

Bullets and bullet fragments
Rifle
Cartridges

5. SECRET SERVICE REPORT

Bullet trajectories

6. FBI REPORTS

Harper skull fragment
Examination of clothing
Autopsy

7. REPORTS

Dr. David O. Davis
Dr. Gerald M. McDonnell
Dr. John Nichols
Soft X-ray and Energy Dispersive X-ray Analysis of Clothing
Prepared by Southwestern Institute of Forensic
Sciences at Dallas
J. Lawrence Angel - October 24, 1977
Clark Panel - 1968
Rockefeller Panel - 1975

Parkland medical reports

8. ARTICLES BY:

Dr. Cyril H. Wecht
Dr. John K. Lattimer

9. MOTION PICTURE FILMS AND SLIDES

Zapruder film
Nix film
Single frame pictures of Zapruder film
Film and slide presentation given by Robert Groden
Harper fragment

Mr. KLEIN. Doctor, do you recognize that document?

Dr. BADEN. Yes, I do.

Mr. KLEIN. What is that?

Dr. BADEN. It is a listing, three pages, of various medical and other materials provided to members of the medical panel in evaluating the cause of death of President Kennedy.

Mr. KLEIN. Using that document, would you tell the committee how the panel went about its examination of the evidence in this case?

Dr. BADEN. The panel initially consisted of a group of forensic pathologists who had previously seen the archival materials and a group that had not. Prior to the meeting of each panel separately, the doctors were provided with various printed materials including copies of the autopsy report, and medical findings and evidence relating to the death of President Kennedy from Parkland Hospital, Warren Commission testimony, and from the Clark and Rockefeller panels. Each member of the panel reviewed these materials, then met individually and collectively at the National Archives where each member reviewed all of the photographic illustrations taken prior to and during the autopsy of the President, all X-rays taken prior to and during the autopsy of the President, the clothing that the President wore at the time of the shooting, various related ballistics material, including a rifle, cartridge shell casings and bullets, and bullet fragments preserved at the Archives.

These are some of the material, listed in these three pages that each member reviewed.

Mr. KLEIN. After meeting at the Archives, did other material become available to the panel?

Dr. BADEN. Yes, in the course of their discussions various panel members suggested additional materials and studies to assist and aid in clarifications of issues and questions that arose after examining the materials provided.

And in this regard, various types of expertise were made available to the panel members, much relating to interpretation of the X-rays taken of the President at the time of the autopsy.

The X-rays were subjected to various techniques that clarified images. The panel members had opportunity to consult with and read reports from various radiologists who are physicians who specialize in taking and interpreting X-rays. The panel did have opportunity to view closely the Zapruder film and sections from the Zapruder film. Studies were requested of soft X-rays and authentication and other studies were performed to assist the panel members in gathering whatever data could be gathered to arrive at conclusions as to the medical aspects of the death.

Mr. KLEIN. Are the members of the panel experienced in evaluating such materials to determine such things as cause of death, number and location of wounds and bullet tracts?

Dr. BADEN. Yes, sir. The full-time occupation of each panel member has been or is investigation of deaths, particularly unnatural deaths, to determine cause of death, every day in the various jurisdictions that the panel members represent.

This is something that is the normal working procedure of each of the doctors assembled.

Mr. KLEIN. Can you give us an approximation of how many autopsies the various members of the panel collectively have performed or been responsible for?

Dr. BADEN. In reviewing the jurisdictions and the length of service of the doctors on the panel, I would estimate that well more than 100,000 medicolegal autopsies have been performed or supervised by the panel members collectively in the course of their official capacities.

Mr. KLEIN. What, if any, relevant materials could not be made available to the panel?

Dr. BADEN. The specific relevant materials not available to the panel have already been mentioned by Professor Blakey pertaining to further examination of brain tissue and microscopic slides.

However, the doctors who performed the autopsy were made available for interview to the panel members and responded on short notice at the very initial meeting of the first panel so that Dr. Humes, Dr. Boswell, subsequently Dr. Ebersole and Dr. Finck were interviewed by the panel members; transcripts were made of the interviews and made available to all the members, especially the interview with Drs. Humes and Boswell at which the second panel members were not present.

Mr. KLEIN. Despite the absence of the brain and the fact that the panel doctors were not present at the autopsy, were the panel members able to reach conclusions with respect to the cause of death, the number of wounds, the location of the wounds, and the path of the bullets through the body?

Dr. BADEN. Yes, sir.

Mr. KLEIN. Are you testifying today as a representative of the entire panel of forensic pathologists?

Dr. BADEN. Yes, I am.

Mr. KLEIN. Did any members of the panel disagree with the conclusions reached by the panel?

Dr. BADEN. The essential conclusions were unanimously agreed to by eight of the panel members. One panel member, Dr. Wecht, did dissent in some important aspects of the conclusions.

Mr. KLEIN. Doctor, since Dr. Wecht will be testifying before the committee today, I will ask you from this point on to confine your testimony to the conclusions reached by the other members of the panel.

Dr. BADEN. Yes.

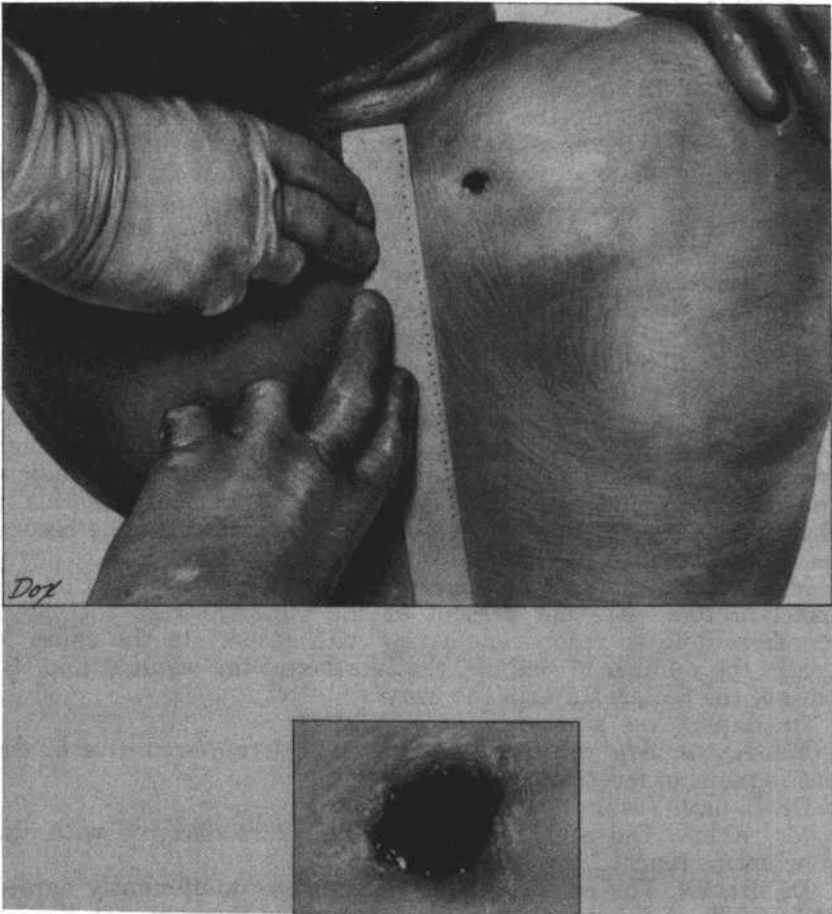
Mr. KLEIN. What was the cause of death of President John F. Kennedy?

Dr. BADEN. President Kennedy died as a result of two gunshot wounds of the head, brain, back and neck areas of the body.

Mr. KLEIN. At this point, Mr. Chairman, I would ask that the drawing marked JFK F-20 be received as a committee exhibit and shown to the witness.

Mr. DODD [presiding]. Without objection, so ordered.

[The above-referred-to document, JFK exhibit F-20, follows:]



JFK EXHIBIT F-20

Mr. KLEIN. I would also ask at this point that Dr. Baden be allowed to move over to the area where the exhibits are shown because a good number of the exhibits will be drawings and diagrams.

Mr. DODD. Dr. Baden, there is a microphone over there for you as well: if you could put that on your tie.

Mr. KLEIN. Doctor, do you recognize that drawing?

Dr. BADEN. Yes, I do.

Mr. KLEIN. What is that drawing of?

Dr. BADEN. This a drawing done by Miss Dox of one of the autopsy photographs taken just prior to the autopsy of President Kennedy.

Mr. KLEIN. What does that particular drawing portray?

Dr. BADEN. This particular drawing shows the back of the President and the head where I am pointing to, and a perforation of the skin of the right upper back with a centimeter ruler alongside.

Mr. KLEIN. Doctor, does this diagram fairly and accurately represent the location of the wound in the President's upper right back?

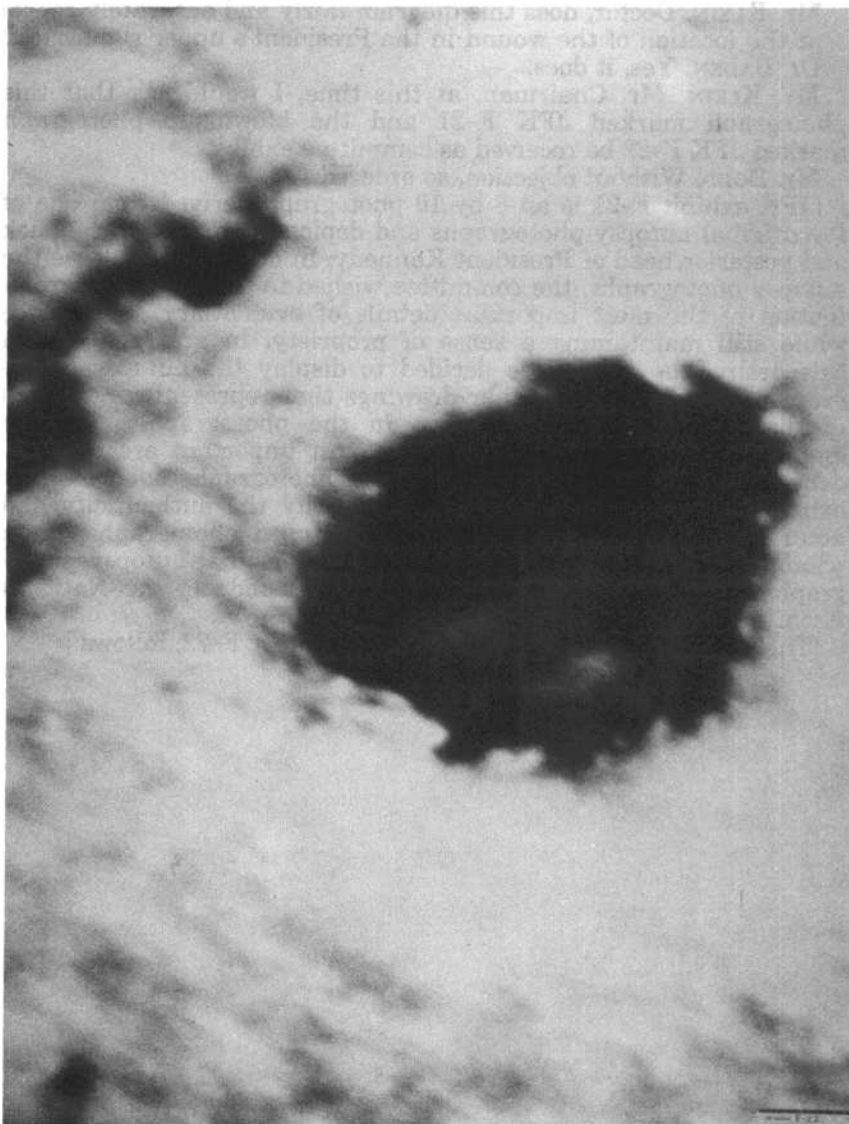
Dr. BADEN. Yes, it does.

Mr. KLEIN. Mr. Chairman, at this time, I would ask that this photograph marked JFK F-21 and the blown up photograph marked JFK F-22 be received as committee exhibits.

Mr. DODD. Without objection, so ordered.

[JFK exhibit F-21 is an 8 by 10 photograph derived from one of the original autopsy photographs and depicts a portion of the back and posterior head of President Kennedy. In deciding to release the autopsy photographs, the committee wished to permit public examination of the most important details of evidentiary significance while still maintaining a sense of propriety. In accordance with this desire, the committee decided to display the autopsy photographs to the public in either drawings that represent large areas of the President's body as seen in the photograph or closely cropped photographs that depict the most important areas of evidentiary concern. The committee used photographs such as JFK exhibit F-21 in the hearings only to verify the authenticity and accuracy of the drawings and closely cropped photographs; these photographs are not being published. The original autopsy photographs and committee copies are in the custody of the National Archives.]

[The above-referred-to document, exhibit JFK F-22, follows:]



JFK EXHIBIT F-22

Mr. KLEIN. Doctor, do you recognize that photograph and that blowup?

Dr. BADEN. The photograph, an 8 by 10 black and white photograph, that I have in my hand is an enlarged detail from one of the autopsy photographs showing the perforation in the right upper back region seen on the diagram; the exhibit alongside is a blowup of the perforation in the right upper back as seen in this photograph.

Mr. KLEIN. So, the blowup is of the wound in the back of the President on the right; is that correct?

Dr. BADEN. That's correct, and this diagram is a diagrammatic representation of this photograph.

Mr. KLEIN. Did the panel have an opportunity to examine the original photograph from which that blowup was made?

Dr. BADEN. The panel had the opportunity and exercised the opportunity to examine, with magnifying lenses, photographs, negatives, transparencies of all of the material available at the Archives.

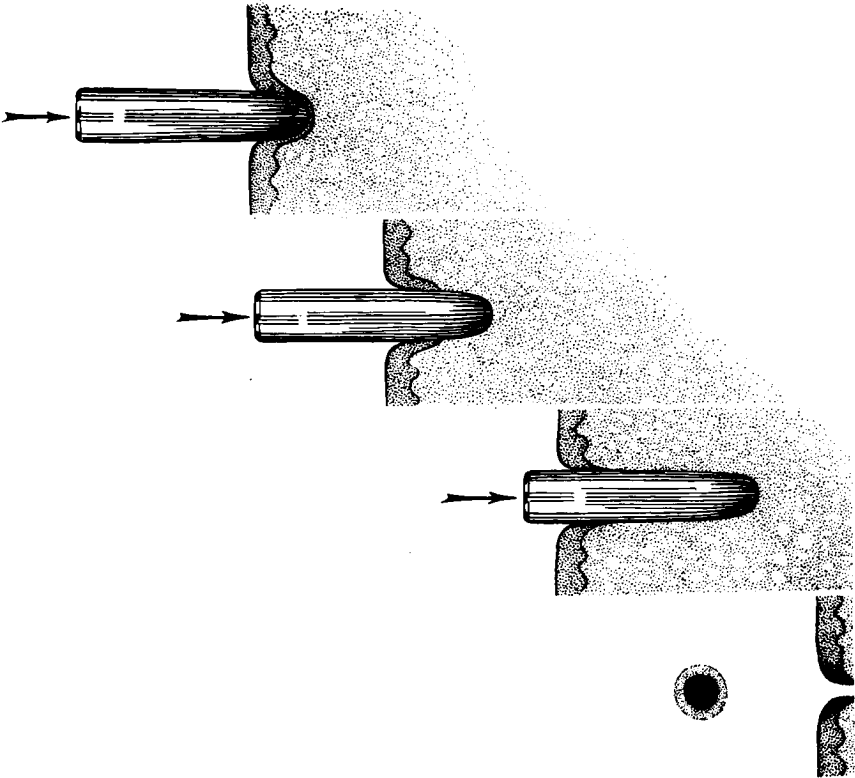
Mr. KLEIN. And using that blowup, would you please explain to the committee what the panel learned from the photograph of the wound on the President's back?

Dr. BADEN. The panel was able to conclude after examining the photographs and the details of the perforation in the right upper back, that this perforation was a gunshot wound of entrance and is characterized uniquely by an abrasion collar, a roughening of the edges around the entrance perforation, which is more apparent in the photographs than the blowup, but which clearly depicts and identifies the perforation as an entrance gunshot wound.

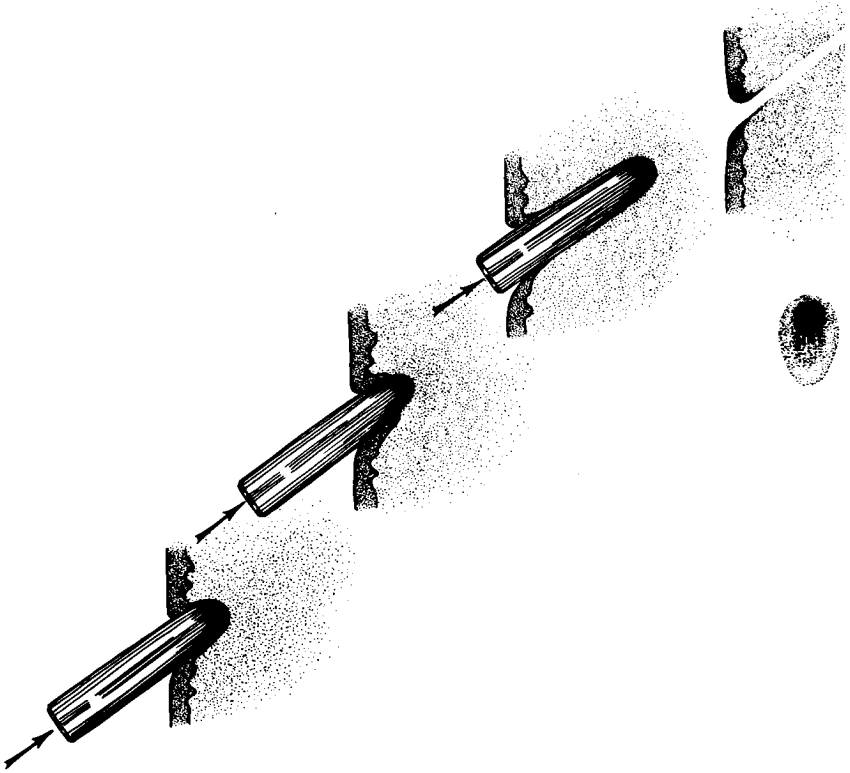
Mr. KLEIN. At this time, Mr. Chairman, I would ask that two diagrams marked JFK F-23 and F-24 be received as committee exhibits.

Mr. DODD. Without objection.

[The above-referred-to documents, JFK F-23 and JFK F-24, follow:]



JFK EXHIBIT F-23



JFK EXHIBIT F-24

Mr. DODD. I would point out while this is occurring, we are missing some members. There is a quorum call going on and they will be coming in and coming out as votes and quorum calls occur during the day.

You may proceed, counsel.

Mr. KLEIN. Doctor, using JFK F-23 and F-24, the two diagrams, would you please explain what an abrasion collar is?

Dr. BADEN. Yes. An abrasion collar is characteristic of an entrance wound produced when a bullet, as seen in these diagrams made by Miss Dox, penetrates the skin from outside the body. The outer surface of the skin here, the epidermis, is depicted darker than the inner tissues underneath; the diagram shows the bullet entering at a 90° angle to the skin, with initial stretching of the outer layer of skin, and rubbing of the bullet against the skin surface as it perforates the overstretched skin causing, after the bullet has passed through and the skin has returned to its normal unstretched condition, a rough, abraded margin of the outer layer of the skin which has a typical darker appearance as in the photographs of President Kennedy. This is referred to as an abrasion collar because it immediately surrounds the perforation of the skin. It tells the forensic pathologists that it was caused by a bullet entering the body and rubbing against the outside of the skin.

When a bullet exits the body through the skin, proceeding from inside the body to the outside, it does not cause, usually, except under special circumstances, this same type of rubbing effect on the edges of the skin.

In this other diagram that Miss Dox has prepared is an example of a bullet entering the skin at an angle. When the bullet enters at an angle, the skin is stretched prior to perforation unequally so that one part of the abrasion collar is wider than another part and this produces a perforation that is assymetric and indicates directionality; thus the abrasion collar establishes not only that it is an entrance wound but also the direction that the bullet is traveling.

When a bullet enters head-on at a 90° angle, the abrasion collar surrounding is equal, uniformly equal. When it enters at an angle, part of the abrasion collar is wider than the other part and this assists in establishing direction of the bullet track.

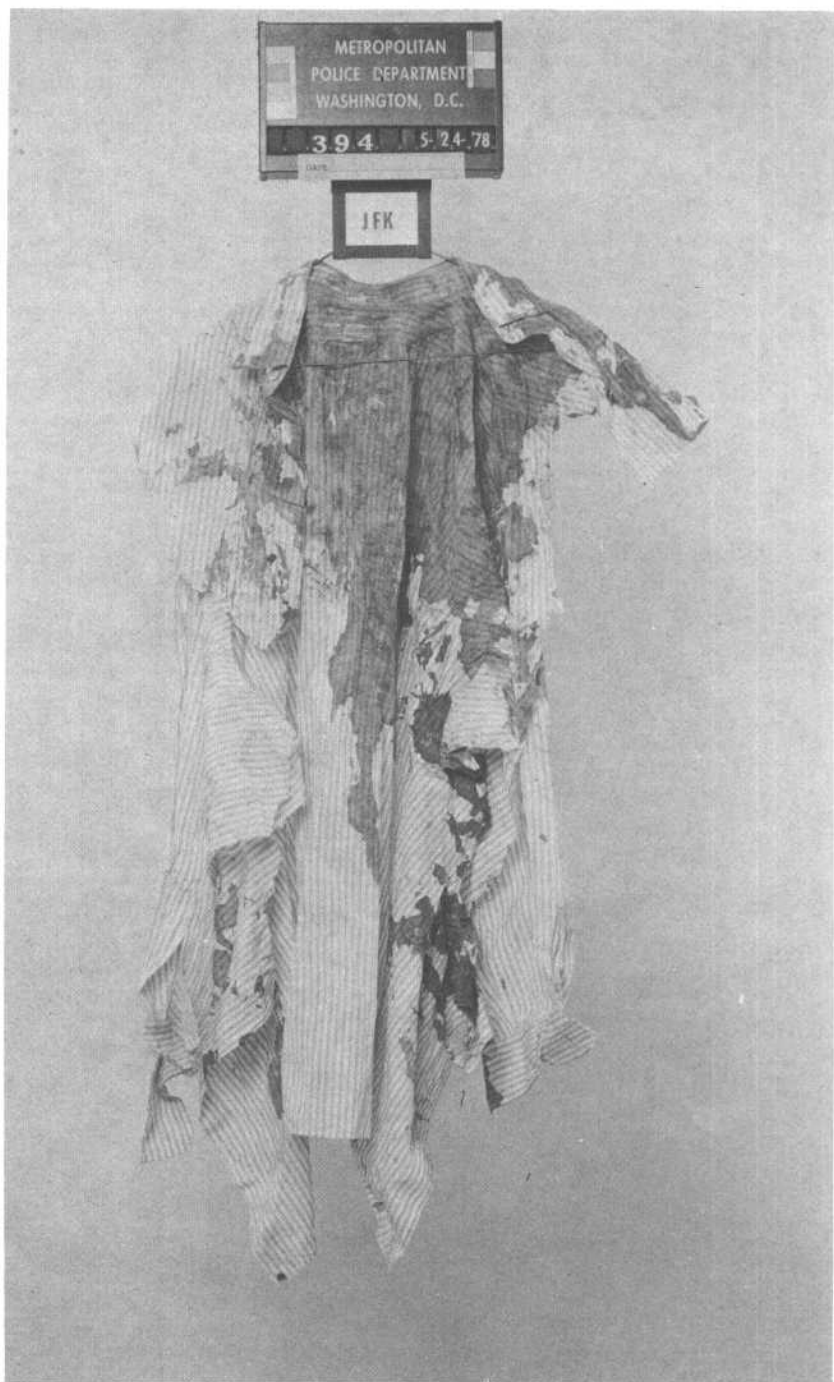
Mr. KLEIN. And the panel found an abrasion collar on the wound of the President's back of the kind you have shown us in these drawings?

Dr. BADEN. Yes, sir. This represents a diagram, a blowup of the actual entrance perforation of the skin showing an abrasion collar. The abrasion collar is wider toward 3 o'clock than toward 9 o'clock, which would indicate a directionality from right to left and toward the middle part of the body, which was the impression of the doctors on reviewing the photographs initially at the Archives.

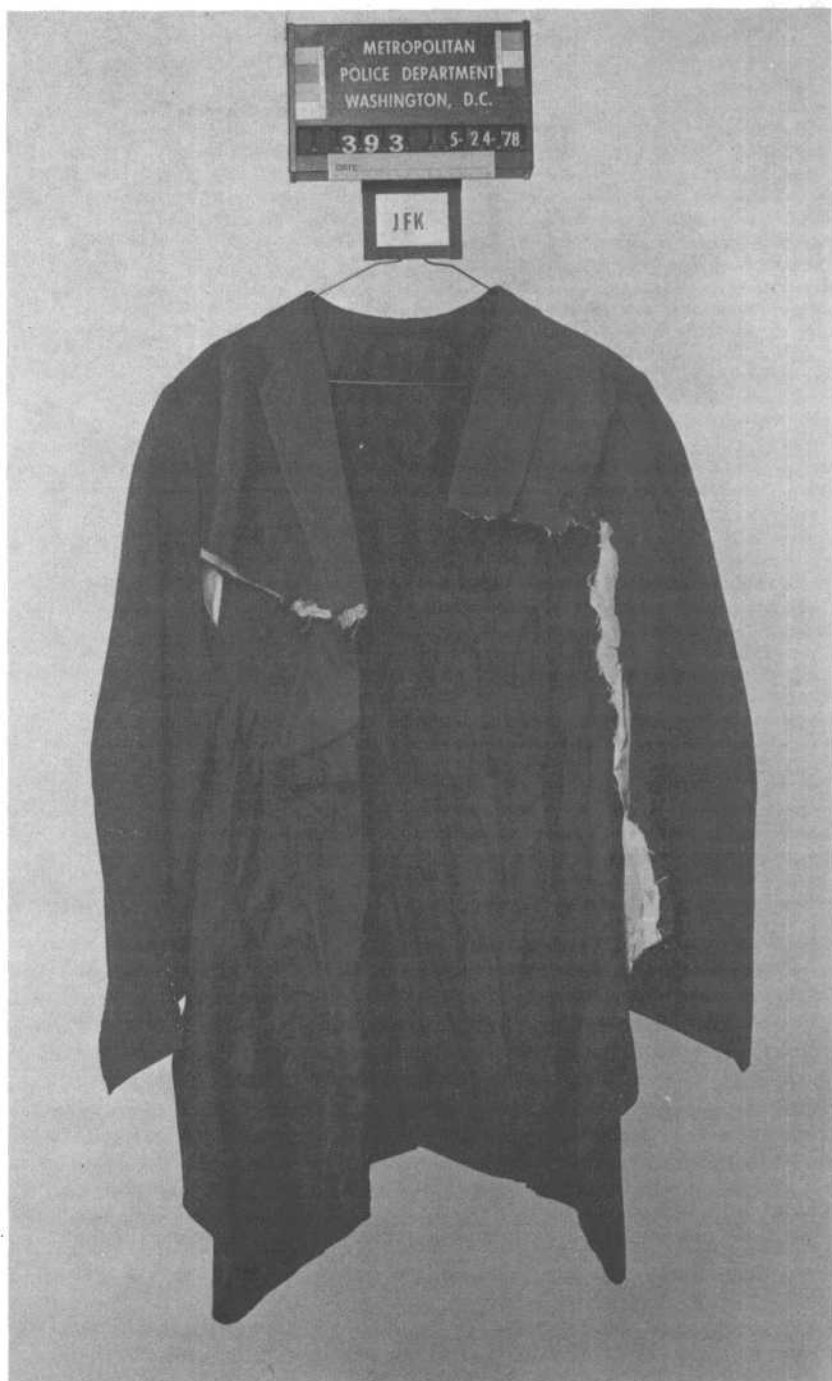Mr. KLEIN. Mr. Chairman, at this time, I would ask that the shirt, jacket, and tie, marked JFK F-25, F-26, and F-27, be received as committee exhibits.

Mr. DODD. Without objection.


[The above-referred-to exhibits, JFK F-25, F-26, and F-27, were received as committee exhibits and photographs made for the record.]



JFK EXHIBIT F-25



JFK EXHIBIT F-26



JFK EXHIBIT F-27

Mr. KLEIN. And shown to the witness.

Doctor, do you recognize that clothing?

Dr. BADEN. Yes, I do, Mr. Klein.

Mr. KLEIN. Where have you seen that?

Dr. BADEN. This clothing was examined by me and by each of the panel members at the Archives where the clothing is kept, preserved, and guarded.

Mr. KLEIN. Whose clothing is that and where did it come from?

Dr. BADEN. This is the clothing worn by President Kennedy at the time of the assassination and does show various perforations in the fabric that were of importance for the medical panel to evaluate.

Present on the mannequin is the jacket and shirt and tie. The jacket and the clothing had been torn at Parkland Hospital by the examining physicians in the course of providing emergency care to the President.

Mr. KLEIN. And with respect to the wounds to the President's back, what did the panel learn from that clothing?

Dr. BADEN. In the jacket and the underlying shirt there is a perforation of the fabric that corresponds directly with the location of the perforation of the skin of the right upper back that, the panel concluded, was an entrance gunshot perforation that entered the back of the President.

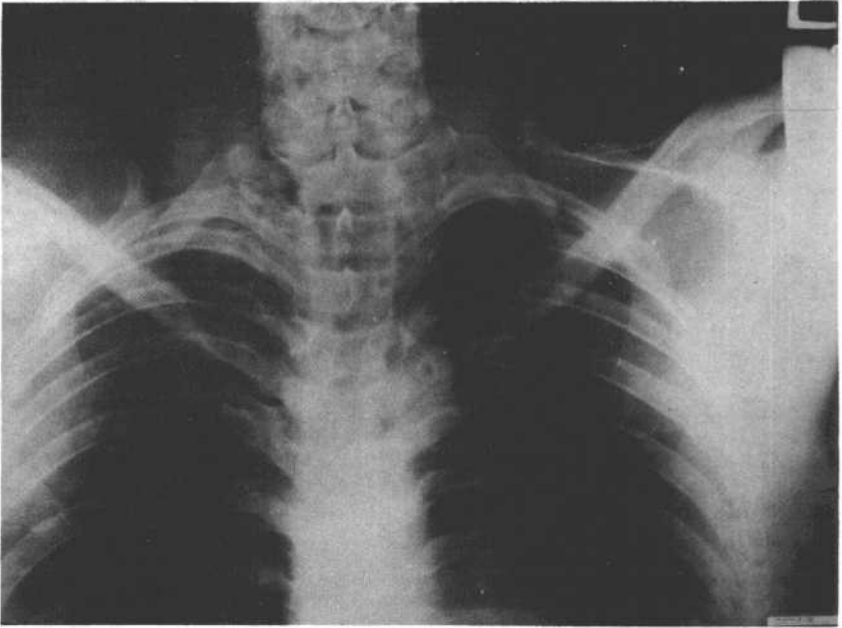This is correspondingly seen in the shirt beneath.

Mr. KLEIN. Mr. Chairman, at this time, I ask that this X-ray marked JFK F-28, this X-ray marked JFK F-29, as well as two blowups marked JFK F-30 and F-31, be received as committee exhibits.

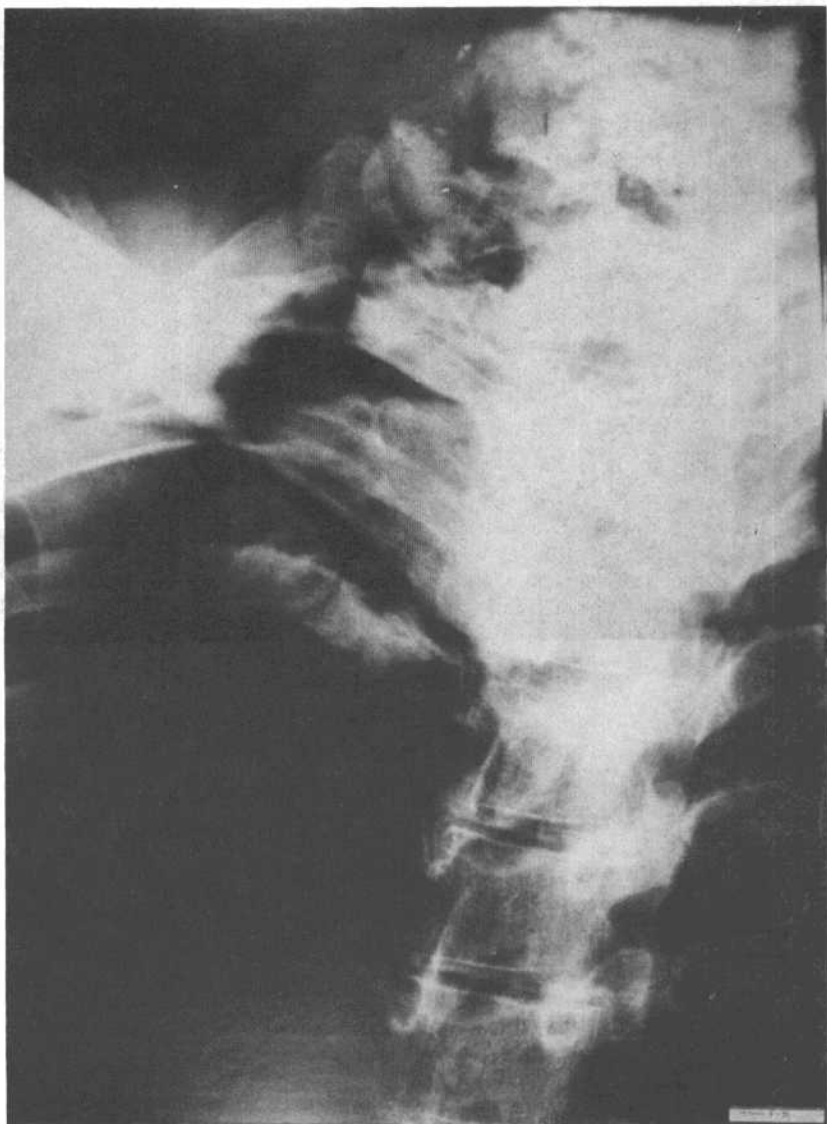
Mr. DODD. Without objection.

[JFK exhibits F-28 and F-29 are two of the original 14 autopsy X-rays kept at the National Archives. They depict the neck and upper chest of President Kennedy. In deciding to release the autopsy X-rays the committee wished to permit public examination of the most important details of evidentiary significance while still maintaining a sense of propriety. In accordance with this desire, the committee decided to display the autopsy X-rays to the public in a cropped fashion. In the hearings the committee used the original X-rays only to verify the authenticity and accuracy of the cropped counterparts; the entire original X-rays are not being published.]

[The above-referred-to exhibits, JFK F-30 and JFK F-31, were received as committee exhibits.]



JFK EXHIBIT F-30



JFK EXHIBIT F-31

Mr. KLEIN. Doctor, do you recognize those blowups and those X-rays?

Dr. BADEN. Yes; these X-rays that I hold are 2 of the 14 X-rays kept at the National Archives and identified to the members of the panel by the radiologist who took the X-rays, Dr. Ebersole. In personal interview Dr. Ebersole told the panel members that the 14 X-rays are the same ones he personally took and received at the time of the autopsy and that he took no other X-rays. These two have been previously labeled 8 and 9 with red tags by Dr. Ebersole

who did not indicate the sequence in which the X-rays were taken when he numbered them.

The blowups are enlargements of portions of the X-rays. The one I am pointing to labeled 9 shows the chest and neck of the President. This area is the lower neck, this is the upper chest, the right lung, the left lung, a portion of the heart shadow; the other X-ray blowup is of archival X-ray No. 8, which was taken after the autopsy had begun and shows the lower neck, the right side of the neck and the upper ribs and spine of President Kennedy.

Mr. KLEIN. What did the panel learn from those X-rays?

Dr. BADEN. The X-rays show, first, that there is no missile present in the body at the time the X-rays were taken. This X-ray, No. 9, was taken before the autopsy, this one, No. 8, during the autopsy. Further, there is evidence of injury to the right side of the neck with air and gas shadows in the right side of the neck and an irregularity of one of the spines, a portion of one spine of the President; that is, the first thoracic vertebra which is also apparent on the blowup and which the panel, and in consultation with the radiology experts, concluded represents a fracture-type injury to that vertebra.

Mr. KLEIN. Are those X-rays consistent with the bullet having passed through the President's body?

Dr. BADEN. Yes, sir. They are consistent with the bullet passing through and no longer being present.

Mr. KLEIN. Mr. Chairman, at this time I ask that these reports marked JFK F-32-F-35 be received as exhibits and shown to the witness.

Mr. DODD. Without objection, so ordered.

[The above-referred-to exhibits, JFK F-32-JFK F-35 were received as committee exhibits.]

JFK EXHIBIT F-32

THE
GEORGE
WASHINGTON
UNIVERSITY
MEDICAL CENTER

Department of Radiology
Diagnostic Division
202) 676-4600

The University Hospital / 901 Twenty-Third Street, N.W. / Washington, D.C. 20037

910958

MEMORANDUM TO: Mr Mark Flanagan, US House of
Representatives Select Committee on
Assassinations
Staff Member

FROM: David O Davis, MD
Professor and Chairman
Department of Radiology
The George Washington University Hospital
Washington DC

PLACE: The George Washington University Hospital
Department of Radiology
Washington DC

DATE: August 23, 1978

SUBJECT: Examination of JFK Autopsy X-Rays

PERSONS PRESENT: Doctor Davis, Mr Mark Flanagan (HSCA), Mr Michael
Leahy (National Archives)

I reviewed the Kennedy skull films labeled #1 and #2, taken at the US Naval Hospital on September 22, 1963, and two aerospace enhanced images of those films.

The findings are as follows:

There is massive calvarial damage, which will be described below. There is a metallic fragment about 9 or 10cm above the external occipital protuberance, which metallic fragment is apparently imbedded in the outer table of the skull. On the frontal view, this metallic fragment is located 2.5cm to the right of midline, and on the lateral view, it is approximately 3-4cm above the lambda. There are a large number of fractures in the calvarium, and the linear fractures seem to more or less emanate from the imbedded metallic fragment, and radiate in a stellate fashion in various directions. There is a large fracture extending directly anteriorly along the sagittal suture, which is, at least at the point visualized, widely separated. This fracture seems to extend into the frontal bone, more or less at the midline, down to

the frontal sinus which is also fractured. There is a sharply defined linear fracture extending laterally from the metallic fragment into the left side of the calvarium, around the parietal bone to the lateral aspect of the skull. Two linear fractures extend inferolaterally from the metallic fragment, one into the occipital bone, about 3cm from the midline, and this fracture crosses the lambdoid suture. The other one is more lateral, and extends down toward the lateral sinus, probably above the lambdoid suture.

Additionally, there is a fracture line extending more or less laterally from the metallic fragment toward the temporal bone on the right side, which is identified only by the anterior edge of the posterior fragment, since there is apparently absence of bone anterior to this line, with the absence present to a point approximately equivalent to where the coronal suture on the right side should be.

There is a fracture fragment inferior to the absent bone, with the corner of the fragment extending down to the parietal squamosal suture, and this fragment is displaced from its normal position as indicated by overlap of the infero and posterior aspects of the fracture fragment. There is a faint line extending inferiorly from the superior aspect or vertex of the skull towards this fragment, which I feel is probably a shadow caused by avulsed scalp and is not explained by absent bone although it projects essentially over the central portion of the absent parietal calvarium that is evident.

The absent bone in the parietal region apparently includes some fragment from the left parietal region, since the fracture seems to cross the midline where there is some lucency, and presumably part of the sagittal suture and sagittal sinus is absent.

The right orbital rim is also fractured laterally, and the roof of the orbit is fractured on the right side, as is the inferior orbital rim, indicating that there is an unstable orbit.

There are a number of metallic fragments extending anteriorly from the inner table of the skull at a point approximately 6cm antero-superiorly from the previously described imbedded metallic fragment. These fragments extend inferoanteriorly across the entire skull and actually project (on other images that I have seen) in a fashion that suggests that the the large fragment is outside the intracranial space. Presumably this represents a metallic fragment in the scalp, although this cannot be accurately determined from this particular examination.

There is some air in the subarachnoid space of the spinal canal, and also apparently in the temporal lobe sulci in the middle fossa, presumably on the right side, but since the fracture is open to the subarachnoid space, this is not at all surprising.

CONCLUSION: There is an extensive comminuted, open, explosive calvarial fracture which seems to radiate in various directions as described above from a central point which is located in the right parietal bone, 3cm from the midline and about 9 or 10cm from the external occipital protuberance. There is absence of a part of the calvarium, beginning near the impact point and extending anteriorly to the coronal suture, with absence of a significant amount of bone in the right parietal and presumably a small amount of left parietal region. There is a displaced fragment or fragments in the right frontal and parietotemporal region, with some overlap of the bone. There is a significant fracture in the frontal region extended into the right orbit and frontal sinus. The fractures also extend, from the posterior impact point, into the occipital bone on both sides.

I neglected to describe in the text of this report an extensive fracture which extends inferolaterally from the impact point toward the left side which probably reaches the temporal bone or at least the mastoid region after crossing a goodly portion of the occipital bone there. It seems apparent that explosive impact occurred in this calvarium. It also seems reasonable to assume that the exit point is near the coronal suture on the right side, about 5 or 6, or perhaps slightly more, cm above the pterion. It is not possible to totally explain the metallic fragment pattern that is present from some of the metallic fragments located superiorly in the region of the parietal bone, or at least projecting on the parietal bone, are actually in the scalp. The frontal view does not give much help in this regard and it is impossible to work this out completely.

I have also reviewed the films numbered 8, 9 and 10, which are of the thoracic region. In addition, I reviewed a film taken at Doctor White's office on Park Avenue in New York, in 1960.

Evaluation of the pre-autopsy film shows that there is some subcutaneous or interstitial air overlying the right C7 and T1 transverse processes. There is disruption of the integrity of the transverse process of T1, which, in comparison with its mate on the opposite side and also with the previously taken film, mentioned above, indicates that there has been a fracture in that area. There

is some soft tissue density overlying the apex of the right lung which may be hematoma in that region or other soft tissue swelling.

Evaluation of the post-autopsy film shows that there is subcutaneous or interstitial air overlying C7 and T1. The same disruption of T1 right transverse process is still present.

On the film of the right side, taken post-autopsy, there are two small metallic densities in the region of the C7 right transverse process. These densities are felt to be artifact, partly because of their marked density, because there is a similar artifact overlying the body of C7, and because these metallic-like densities were not present on the previous, pre-autopsy film. Therefore, I assume that these are screen artifacts from debris present in the cassette at the time that this film was exposed.

OPINION: There is evidence of interstitial air on the pre-autopsy film, and evidence of a right T1 transverse process fracture, both on the pre-autopsy and post-autopsy film. The fracture fragments are not significantly displaced. I do not feel that there is any evidence of foreign body on these films, and that the small metallic density mentioned above, overlying the C7 transverse process region, is actually an artifact.

DOD/mhw

JFK EXHIBIT F-33

DEPARTMENT OF RADIOLOGY
THE HOSPITAL OF THE GOOD SAMARITAN616 SOUTH WITMER STREET
LOS ANGELES, CALIFORNIA 90017*Diagnostic Radiology*ROBERT E. LEVY, M.D.
GERALD M. McDONNELL, M.D.
JOSEPH L. WESTOVER, M.D.
PHILLIP C. SHU, M.D.
GERALD B. ISA, M.D.
HAYWARD N. LEVENICK, M.D.
WILLIAM C. SCHLEINER, M.D.
TELEPHONE 488-8251*Radiation Therapy*R. WILBUR MELBYE, Ph.D., M.D.
DONALD P. ANDERSON, M.D.
TELEPHONE 488-8981*Radiation Physicists*RICHARD M. GARVER, M.S.
MELISSA C. MARTIN, M.S.*Nuclear Medicine*LEONARD A. SWANSON, M.D.
TELEPHONE 488-8245TO: Michael Goldsmith
Senior Staff Counsel
Select Committee on Assassinations
U.S. House of Representatives
3342 House Office Building, Annex 2
Washington, D.C. 20515

DATE: August 4, 1978

SUBJECT: Report of G.M. McDonnell, M.D. concerning observation, analysis, and conclusions in connection with radiographic images and enhanced images attributed to President John F. Kennedy.

This report replaces my report of March 8, 1978 and supplements my presentation of July 21, 1978 in the Rayburn Building, Washington, D.C.

I was exposed to radiographic images identified by the number 21296 at Aerospace Corporation, El Segundo, California on March 7, 1978. At my suggestion portions of these radiographs were digitized and enhanced by Aerospace Corporation for further observation and analysis.

I participated in discussions during the photographic evidence panel on 6 and 7 April 1978 during which time I dialogued with Dr. James Weston concerning my interpretation of these radiographs and the enhanced images.

On 2 June 1978 I again viewed and analyzed the radiographic images at the National Archives Building in Washington, D.C. As requested I also interpreted and analyzed skull and sinus radiographs obtained during the lifetime of the subject for the specific purpose of authenticating the radiographs obtained before and after the autopsy.

The original radiographs seen on 7 March were:

- a. An attempted anteroposterior projection of a skull identified as:
21296 (numbers upside down)
US Naval Hospital
NNMC Bethesda Maryland
11 22 63
- b. Right lateral projection of a skull with the same identification symbols.
- c. Left lateral projection of a skull with the same identification symbols.

- d. Three radiographs of three fragments of bone unidentified by symbols.
- e. An anteroposterior projection of a chest with the same identification symbols as a, b, c above. This radiograph was obtained with the thoracic cage intact, i.e., before autopsy.
- f. An anteroposterior projection of a chest with the same identification as e above. This radiograph was obtained after the thorax had been opened and the lungs and mediastinal contents had been removed.

The findings and interpretation of the skull films are:

1. Nearly complete loss of right parietal bone, the upper portion of the right temporal bone, and a portion of the posterior aspect of the right frontal bone.
2. Subdural air over the left parietal hemisphere.
3. Multiple skull fractures and disruption of continuity of the bony tables.
4. A metallic fragment on the outer table of the right occipital bone 9.6 cm. above the mid portion of the external occipital protuberance (EOP). 1 cm. above the metallic fragment is a depressed fracture from which stellate type fractures "radiate" into both occipital bones, the right parietal bone and the right temporal bone. These are vividly and convincingly displayed in the enhanced images, specifically the "anteroposterior" (AP) projection of the skull. The metallic fragment in this projection is nearly spherical in contour.
5. There is a fracture line extending through the floor of the sella turcica with bony fragments in the sphenoid sinus. This is vividly depicted in the enhanced images.
6. There are fracture lines through the anterior and posterior aspects of the right frontal sinus with air in this sinus. There is a metallic fragment above the sinus appearing to be between the bony tables of the frontal bone.
7. There is elevation of the galea medial and lateral, as well as anteriorly, to the depressed fracture in the right occipital bone. A small metallic fragment lies medial to the fracture site between the galea and the outer table of the skull.

The mechanism of damage to the skull is concluded to be:

1. A low mass, high velocity, metallic projectile penetrated the right occipital bone at the area of the depressed fracture, leaving behind the spherical shaped contoured metallic fragment in 4 above.
2. The reflected shock wave from the outer table propelled a metallic fragment medially as in 7 above.
3. The stellate type "radiating" fractures as in 4 above resulted from the entering metallic projectile.
4. (also 8 in findings).

A linear alignment of tiny metallic fragments is associated with the entry, path of travel, and exit in the posterior aspect of the right frontal bone.

CHEST

The pre-autopsy radiograph of the chest shows air in the soft tissues of the right supraclavicular area soft tissues.

There is an undisplaced fracture of the proximal portion of the right transverse process of T1 (or the region of the costovertebral junction).

There is no evidence of fracture of the cervical spine or its associated appendages.

In the post autopsy film of the thoracic region there is debris in the radiographic image superimposed over the area to the right of the C7 vertebral body.

In the enhanced post autopsy image of the same area, there appears to be fractures of the posterior aspects of the 2nd, 3rd, and 4th ribs. These are artifacts.

Authentication of Radiographs.

The following radiographs were provided at the National Archives, Washington, D.C. on June 2, 1978.

- a. A left lateral skull radiograph dated 8/17/60 performed by Groover, Christie and Merritt, with number 336042 and blue ink writing of "Kennedy".
- b. A paranasal sinus series performed by (or for) Stephen White, M.D., 521 Park Ave. NYC, dated 8/14/60, and identified by number 202617.

The following anatomical and bony structures are common and identical to all three sets of radiographs.

1. The thickness and contour of the frontal bones.
2. Deviation of the mid portion of the nasal septum from right to left.
3. The contour of the frontal sinuses.
4. The contour and shape of the sella turcica.
5. The contour of the posterior clinoids.
6. The contour and calcification of the posterior clinoid ligaments.
7. There is thickening of the medial and superior aspects of the mucoperiosteal margin of the left frontal sinus. This is less severe in the radiographs of 8/14/60 and 8/17/60 than in the radiographs of 11/22/63. The general margin of this tissue swelling is similar in all three studies.

In my opinion the three sets of radiographs are positively and without controversy, of the same individual. It is impossible to simulate the referenced anatomical landmarks, the nasal septum deviation, and the documentation of the progressive disease process in the left frontal sinus.

Enhancement of the Radiographic Images.

The digitized and enhanced images produced by Aerospace Corporation permitted definitive observation and analysis of the original radiographs. Further, enhancement permitted analysis or elimination of artifacts on the images. The most vivid result is the clear definition of the multiple fractures radiating from the area of the entrance of the penetrating missile in the right occipital bone.

"Doctored" of the Radiographic Images"

In my opinion the images which I have seen have not been "doctored" or "treated" in any fashion, except for:

- a. Two small areas of thermal damage resulting from a light source held too close to the "anteroposterior" image. These were reported to be present on an observation report dated November 1, 1966 and validated by signature November 10, 1966. This report is in the National Archives. Interestingly, the enhanced images downgrade the prominence of the "burns" while enhancing the true radiographic image.
- b. Minor "staining" or discoloration of the images due to incomplete processing of the film in the developing process. This discoloration has, and will continue to be, more prominent with the passage of time.

The linear opacities associated with the images have been said to be the result of manipulation. These opacities or normal grid lines from the grid used to eliminate "scatter fogging" of the images at the time of exposure of the films and therefore represent normal images without evidence of manipulation.

Final Summary:

1. The observations of the findings are as stated and validated by the enhanced images.
2. The described mechanisms of damage are the writer's professional opinion.
3. The radiographs observed are incontrovertibly of the same individual during life and the early post mortem period.
4. The observed radiographic images have not been altered in an effort to provide a false image.


G.M. McDonnell, M.D.

GMM:st

Enhancement of Radiographic Images.

The digitized and enhanced images produced by Aerospace Corporation permitted definitive observation and analysis of the original radiographs. Further, enhancement permitted analysis or elimination of artifacts on the images. The most vivid result is the clear definition of the multiple fractures radiating from the area of the entrance of the penetrating missile in the right occipital bone.

Alteration or "Doctoring" of the Radiographs.

There have been allegations that the post mortem radiographic images have been modified or altered ("doctored") to produce misinformation and therefore improper conclusions. An altered image should be readily apparent by:

- a. Observation of a difference in density of the images,
- b. discontinuity of anatomical structures,
- c. alteration of continuity of an abnormal pattern, or
- d. production of an image which is not anatomical or an image of an impossible pathologic process.


The radiographic images both ante mortem and post mortem, have NOT been altered in any fashion, except for:

- a. Two small areas of thermal damage resulting from a light source held too close to the "anteroposterior" image. These were reported to be present on an observation report dated November 1, 1966 and validated by signature November 10, 1966. This report is in the National Archives. Interestingly, the enhanced images downgrade the prominence of the "burns" while enhancing the true radiographic image.
- b. Minor "staining" or discoloration of the images due to incomplete processing of the film in the developing process. This discoloration has, and will continue to be, more prominent with the passage of time.

The linear opacities with the post mortem have been said to be the result of manipulation. These opacities are normal grid lines from the grid used to eliminate "scatter fogging" of the images at the time of exposure of the films and therefore represent normal images without evidence of manipulation.

Final Summary:

1. The observations of the findings are as stated and validated by the enhanced images.
2. The described mechanisms of damage are the writer's professional opinion.
3. The radiographs observed are incontrovertibly of the same individual during life and the early post mortem period.
4. The observed radiographic images have not been altered in an effort to provide a false image.


G.M. McDonnell, M.D.

GMM:st

JFK EXHIBIT F-34

OUTSIDE CONTACT REPORTDATE 2/27/78 TIME _____

I. Identifying Information:

Name Dr. Norman Chase Telephone _____Address NYU Medical Center, New YorkType of Contact: Telephone
 Person

II. Summary of Contact:

Dr. Chase examined the JFK and Connally X-rays in the presence of Dr. Michael Baden, Mark Flanagan, and Andy Purdy.

He made preliminary observations before we focussed his attention on particular areas of interest to the medical panel.

JFK: Skull X-ray - The lateral skull X-ray indicated that the missile ". . .blew the top of the head off. . .striking with enormous power." The wound was massive, not the kind he would expect from a single, jacketed bullet hitting straight on; it was possibly tumbling or hit on an angle. The entry point was visible on the upper rear head. Regarding the anterior-posterior X-ray, Dr. Chase noted the large metal fragment prominent in the X-ray and said he believes it corresponds to the metal fragment in the rear of the head as evi-

III. Recommended Follow-up (if any):

Signature: Andy Purdy Mark Flanagan

Form #5

dence on the lateral view. He said the frontal fragment would appear higher (than the aforementioned fragment) in the anterior view (and slightly left of center).

Dr. Chase said the head X-rays show extensive comminuted fractures of the calvarium. He said that while it is unclear exactly what happened to the top of the skull because of the extensive damage, he is sure that the skull was not perforated by a missile at any point below the one he designated as an entrance wound. When referred by Dr. Baden to the lower skull region and asked what his response would be if told that the autopsy surgeons believed there was a wound of entry there, he said he would say they were wrong.

He said the degree of damage to the skull and the fact that there was "little residual material" led him to believe the missile was jacketed. He said there is no evidence in the X-rays of a shot coming from the front or of more than one bullet striking the skull; for there to have been a second bullet, Dr. Chase said there would have to be another exit point in the skull or a bullet which was left behind (which entered the exit hole of the one bullet which entered in the upper rear of the head).

Regarding the circular temporal bone area, Chase said it appeared to represent normal skull thinning at that point but said there could be bone missing, noting the area was ". . . awfully luscent." When viewing a pre-assassination lateral skull X-ray, Dr. Chase said he believed there was

exit of bone from the temporal area, the zygomatic process (lateral view). He also noted fracture of the right orbit.

In the neck X-ray, Chase noted the presence of a metal fragment or artifact in the area of the transverse process--definitely not a bone fragment. The first rib appeared to be separated from the sternum but he had trouble noting specific evidence of a missile passing through the first or second rib. Air was noted in the subcutaneous tissue in this same region, caused by the passage of a missile and/or air entering the region due to the tracheostomy incision. He said the object present was not bone because it was too small and too dense; the little trail of dots near the fragment were believed to be artifacts. The object was about 1 mm x 2½mm--"very small." Chase said that if a break occurred in T-1 it was peculiar and had no displacement. He said that extra work on X-ray #9 might bring out this fragment in another view.

CONNALLY; Regarding the thigh X-ray, Chase said there was a metal fragment in the subcutaneous tissue and there was no fragment in the femur; the object thought to be such a fragment is artifact.

Regarding the chest X-ray, he said there was no evidence of pneumothorax. The fifth rib appears fractured in the post-operative X-ray but is not evident in the pre-op (region of posterior axillary line or mid-axillary line). Soft tissue damage is evidenced by the presence of air and blood.

Dr. Chase had no recommendations for experts in forensic radiology.

JFK EXHIBIT F-35

KENNEDY

006132

OUTSIDE CONTACT REPORTDATE 2/27/78 TIME 1:30PM

I. Identifying Information:

Name Dr. William B. Seaman Telephone _____Address Columbia Presbyterian Hospital, New York CityType of Contact: Telephone
 Person

II. Summary of Contact:

Dr. Seaman examined the JFK and Connally X-rays
in the presence of Dr. King, Dr. Michael Baden, Mark Flanagan
and Andy Purdy. He made his preliminary observation before
his attention was focused on areas of particular interest to
the medical panel.

JFK- Regarding the lateral skull X-ray, Dr. Seaman
said pieces of metal were strewn in a track-like manner.
Fractures were evident through the upper part of the right eye,
including the top and bottom of the right orbit. The bottom
of the frontal sinus was fractured. At the upper rear skull
point of possible defect in the skull, Dr. Seaman said it could
be an entrance wound and could not be a missile exit wound.
He said he could not denote beveling of the skull at that point.

III. Recommended Follow-up (if any):

Andy Purdy Mark Flanagan

He found inferences difficult to draw from the extensive damage to the top of the skull, which includes overlapping skull pieces. The lower head was fairly intact with no evidence of entrance or exit in the region ("very unlikely"). The upper point (mentioned earlier) "suggests entry but is not conclusive."

Regarding the neck X-ray, Dr. Seaman said there was a fragment-like object present near the transverse process which is too dense to be bone ("fairly confident"). He said the transverse process appears abnormal with air present (possibly by-product of tracheostomy), calling it "...highly suspicious compared with the other side! He thinks he can "... see the fragment separated" (also in #9) and concludes there is a possible fracture in C-7.

Connally - Wrist - comminuted fracture with fragments. He was not sure if the fragments were on the entrance (volar) or exit sides. Dr. Seaman concludes from the spatial orientation that they are fragments of metal.

Thigh - Dr. Seaman denoted a fragment of metal in the subcutaneous tissue, characterized by a tail-like end which makes it recognizable on both thigh X-rays and ensures it is not bone. There is no metal fragment in the femur.

Chest - Dr. Seaman noted an area of consolidation and fluid in the right chest. In the 5th rib he noted a fracture and fragment of bone in the anterior axillary line with evidence of hemorrhage and air in the axilla.

Regarding the possible existence of a higher fracture in the fifth rib Dr. Seaman said he was a "little skeptical" of it as a fracture because he couldn't see it fractured all the way

through ("possibly a lung marking"). He said subsequent healing as evidenced in a subsequent (even now) X-ray might provide more information about exactly what happened. Dr. Seaman found no evidence of metal fragments in the chest and couldn't form an opinion as to the nature of the object visible on the left side.

Dr. Seaman had no one to recommend who is an expert in forensic radiology. He did say Dr. Juan Taveras of Massachusetts General Hospital (Boston) is a skull expert who might have something to contribute.

Mr. KLEIN. Doctor, looking at those reports, do you recognize them?

Dr. BADEN. Yes, sir. These are reports of the X-rays from physician experts consulted by the panel members and submitted to us for review and incorporation into our conclusions as to the medical aspects of the death of the President.

Mr. KLEIN. What were the names of the doctors to whom you submitted the X-rays?

Dr. BADEN. The doctors are Dr. David Davis, who is chairman of the Radiology Department at George Washington University here in Washington and who has been extremely helpful to the panel in interpreting the X-rays and who has worked with us in making diagrams to illustrate the injuries seen on X-ray.

Dr. Norman Chase, who is chairman of the Radiology Department at New York University, Bellevue Medical Center. **Dr. William Seaman,** chairman of the Department of Radiology at Columbia Presbyterian Hospital in New York City. And **Dr. McDonnel** of Los Angeles, Calif., Department of Radiology, Hospital of the Good Samaritan, who performed various specialized tests on the X-rays for the benefit of the panel.

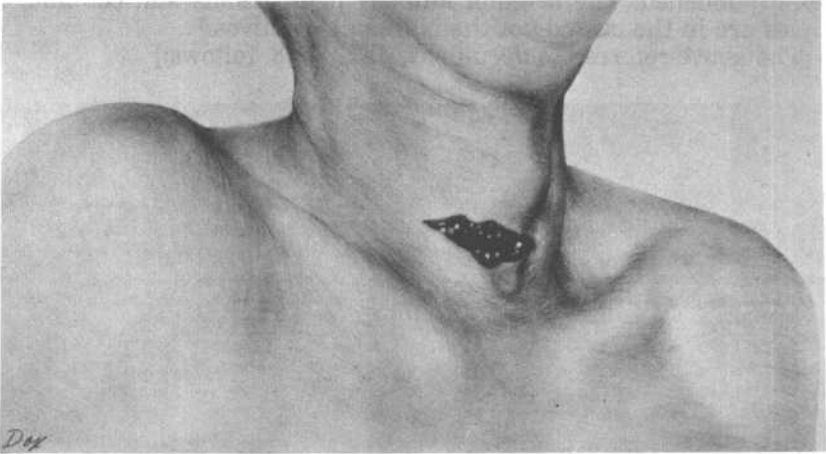
Mr. KLEIN. Doctor, were the reports of these experts consistent with the panel's evaluation of the JFK X-rays?

Dr. BADEN. Yes, sir; they were consistent and gave additional evidence to the panel for reaching its conclusions.

Mr. KLEIN. Mr. Chairman, at this time, I would ask that the drawing marked JFK F-36 be received as a committee exhibit.

Mr. DODD. Without objection, so ordered.

[The above-referred-to document, JFK F-36, follows.]



JFK EXHIBIT F-36

Mr. KLEIN. Doctor, do you recognize that drawing?

Dr. BADEN. Yes, this is a drawing of a photograph taken prior to the beginning of the autopsy of the President showing the neck region, the upper chest region, and a wound in the front of the neck.

Mr. KLEIN. Does this diagram fairly and accurately represent the location of the wound on the front of the President's neck?

Dr. BADEN. Yes, it does.

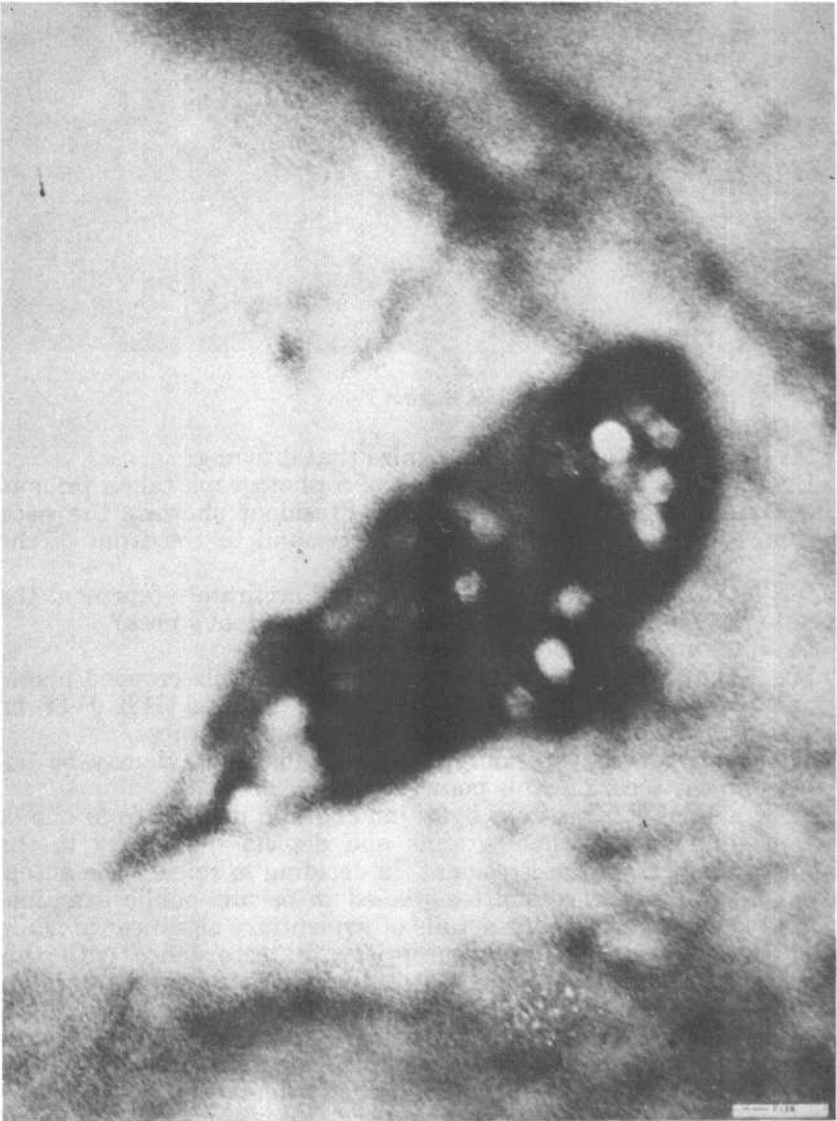
Mr. KLEIN. Mr. Chairman, I would ask that this cropped photograph marked JFK F-37 and the blowup marked JFK F-38 be received as committee exhibits and shown to the witness.

Chairman STOKES [presiding]. Without objection, it may be entered into the record at this point.

[JFK exhibit F-37 is an 8 by 10 photograph derived from one of the original autopsy photographs and depicts the injury to the front of the neck of the President. In deciding to release the autopsy photographs, the committee wished to permit public examination of the most important details of evidentiary significance while still maintaining a sense of propriety. In accordance with this desire, the committee decided to display the autopsy photographs to the public in either drawings that represent large areas of the President's body as seen in the photograph or closely cropped photographs that depict the most important areas of evidentiary concern. The committee used photographs such as JFK F-37 in the hearings only to verify the authenticity and accuracy of the drawings and closely cropped photographs; these photographs are not

being published. The original autopsy photographs and committee copies are in the custody of the National Archives.]

[The above-referred-to document, JFK F-38, follows:]



JFK EXHIBIT F-38

Mr. KLEIN. Doctor, do you recognize that photograph and that blowup?

Dr. BADEN. Yes, sir. The black and white 8 by 10 photograph I have in my hand is from a photograph taken of the President at the time of the autopsy and the blowup is a detail from that

photograph showing the injury to the front of the neck as depicted in the drawing before us.

Mr. KLEIN. Using the blowup, would you tell us what the panel learned from the photograph?

Dr. BADEN. The panel learned from the photograph that a tracheostomy, incision, an incision to aid the dying President in breathing, had been made on the front of the neck at the hospital and is a typical type of tracheostomy incision; and the panel also noted a semicircular defect at the lower margin of that tracheostomy which required further evaluation.

Mr. KLEIN. Doctor, in speaking to and reading the reports of the doctors who attended President Kennedy after he was shot, in Parkland Hospital, did you learn any further information about that wound of the neck?

Dr. BADEN. Yes. In the reports made available to us from prior testimony, prior medical reports, and from current interviews with the doctors, it is apparent that there was a perforation, a perforating wound, of the front of the neck present when the President was received at Parkland Hospital; and that the tracheostomy incision, the incision to put in a breathing tube, was made through that perforation of the skin and did modify and change the hole in the manner seen here from a circular hole to a semicircle, that remains.

Mr. KLEIN. Doctor, directing your attention to the clothing already received as exhibits, would you tell us what the panel learned from that clothing with respect to the wound of the President's neck?

Dr. BADEN. Yes, sir. On examining the clothing of the President, there is present in the left upper portion of the shirt, just beneath the left shirt collar, a slit-like tear. This slit-like tear corresponds directly with the area of perforation in the anterior neck seen on the photographs taken prior to the autopsy and is characteristic of a bullet perforation of exit in which the perforation is not necessarily as round as the entrance perforation.

The entrance perforation on the back is a round perforation typical for an entrance wound. The perforation in the front of the shirt, slit-like, is typical for an exit perforation of a missile.

There is also associated with this tear in the shirt fabric a tear or nick of the tie the President was wearing, which corresponds to that same area of the body when the tie is made into a knot as he was wearing at the time of the shooting.

Mr. KLEIN. Doctor, in addition to examining the foregoing evidence, did the panel have an opportunity to examine the autopsy protocol report, the autopsy descriptive sheet, and the autopsy supplementary report?

Dr. BADEN. Yes, sir.

Mr. KLEIN. Mr. Chairman, I would ask that these three reports marked JFK F-42 through F-44 be received as exhibits and shown to the witness, and F-45, an enlargement of F-44.

Chairman STOKES. Without objection, they may be received and entered into the record at this point.

[The above-referred-to exhibits, JFK F-42 to JFK F-44, follow:]

JFK EXHIBIT F-42

OPTIONAL FORM NO. 10
5010-104

UNITED STATES GOVERNMENT

Memorandum

4-1

U. S. Secret Service

TO : J. Lee Rankin
General Counsel


FROM : James J. Rowley
Chief, U. S. Secret Service

SUBJECT: Autopsy Report

DATE: December 20, 1963

Commission No 77

There is attached standard form 503, a clinical record of the autopsy protocol prepared by the Naval Medical School, Bethesda, Md., relative to the autopsy performed on President John F. Kennedy.



Standard Form 503
Revised August 1954
Prescribed
By Bureau of the Budget
Circular A-32 (Rev.)

CLINICAL RECORD		AUTOPSY PROTOCOL			A63-272 (JHH:ec)		
DATE AND HOUR DIED		A. M.	DATE AND HOUR AUTOPSY PERFORMED	A. M.	CHECK ONE		
22 November 1963 1300(CST)		P. M.	22 November 1963 2000(EST)	M.	FULL AUTOPSY	HEAD ONLY	TRUNK ONLY
PROSECTOR (497831)		ASSISTANT (489878)					
CDR J. J. HUNES, MC, USN		CDR "J" THORNTON BOSWELL, MC, USN		X			
CLINICAL DIAGNOSES (Including operations)		LCOL PIERRE A. FINCK, MC, USA (04 043 322)					

Ht. - 72½ inches
Wt. - 170 pounds
Eyes - blue
Hair - Reddish brown

PATHOLOGICAL DIAGNOSES

CAUSE OF DEATH: Gunshot wound, head.

APPROVED: *[Signature]*

J. J. HUNES, CDR, MC, USN

MILITARY ORGANIZATION (If App. required)	AGE	SEX	RACE	IDENTIFICATION NO.	AUTOPSY NO.
PRESIDENT, UNITED STATES	46	Male	Cauc.		A63-272
PATIENT'S IDENTIFICATION (For typed or written entries give Name, last, first, middle, grade, date, hospital or medical facility)				REGISTER NO.	WARD NO.
KENNEDY, JOHN F. NAVAL MEDICAL SCHOOL					

AUTOPSY PROTOCOL
Standard Form 503

CLINICAL SUMMARY:

According to available information the deceased, President John F. Kennedy, was riding in an open car in a motorcade during an official visit to Dallas, Texas on 22 November 1963. The President was sitting in the right rear seat with Mrs. Kennedy seated on the same seat to his left. Sitting directly in front of the President was Governor John B. Connolly of Texas and directly in front of Mrs. Kennedy sat Mrs. Connolly. The vehicle was moving at a slow rate of speed down an incline into an underpass that leads to a freeway route to the Dallas Trade Mart where the President was to deliver an address.

Three shots were heard and the President fell forward bleeding from the head. (Governor Connolly was seriously wounded by the same gunfire.) According to newspaper reports ("Washington Post" November 23, 1963) Bob Jackson, a Dallas "Times Herald" Photographer, said he looked around as he heard the shots and saw a rifle barrel disappearing into a window on an upper floor of the nearby Texas School Book Depository Building.

Shortly following the wounding of the two men the car was driven to Parkland Hospital in Dallas. In the emergency room of that hospital the President was attended by Dr. Malcolm Perry. Telephone communication with Dr. Perry on November 23, 1963 develops the following information relative to the observations made by Dr. Perry and procedures performed there prior to death.

Dr. Perry noted the massive wound of the head and a second much smaller wound of the low anterior neck in approximately the midline. A tracheostomy was performed by extending the latter wound. At this point bloody air was noted bubbling from the wound and an injury to the right lateral wall of the trachea was observed. Incisions were made in the upper anterior chest wall bilaterally to combat possible subcutaneous emphysema. Intravenous infusions of blood and saline were begun and oxygen was administered. Despite these measures cardiac arrest occurred and closed chest cardiac massage failed to re-establish cardiac action. The President was pronounced dead approximately thirty to forty minutes after receiving his wounds.

The remains were transported via the Presidential plane to Washington, D.C. and subsequently to the Naval Medical School, National Naval Medical Center, Bethesda, Maryland for postmortem examination.

GENERAL DESCRIPTION OF BODY:

The body is that of a muscular, well-developed and well nourished adult Caucasian male measuring 72½ inches and weighing approximately 170 pounds. There is beginning rigor mortis, minimal dependent livor mortis of the dorsum, and early algor mortis. The hair is reddish brown and abundant, the eyes are blue, the right pupil measuring 8 mm. in diameter, the left 4 mm. There is edema and ecchymosis of the inner canthus region of the left eyelid measuring approximately 1.5 cm. in greatest diameter. There is edema and ecchymosis diffusely over the right supra-orbital ridge with abnormal mobility of the underlying bone. (The remainder of the scalp will be described with the skull.)

There is clotted blood on the external ears but otherwise the ears, nares, and mouth are essentially unremarkable. The teeth are in excellent repair and there is some pallor of the oral mucous membrane.

Situated on the upper right posterior thorax just above the upper border of the scapula there is a 7 x 4 millimeter oval wound. This wound is measured to be 14 cm. from the tip of the right acromion process and 14 cm. below the tip of the right mastoid process.

Situated in the low anterior neck at approximately the level of the third and fourth tracheal rings is a 6.5 cm. long transverse wound with widely gaping irregular edges. (The depth and character of these wounds will be further described below.)

Situated on the anterior chest wall in the nipple line are bilateral 2 cm. long recent transverse surgical incisions into the subcutaneous tissue. The one on the left is situated 11 cm. cephalad to the nipple and the one on the right 8 cm. cephalad to the nipple. There is no hemorrhage or ecchymosis associated with these wounds. A similar clean wound measuring 2 cm. in length is situated on the antero-lateral aspect of the left mid arm. Situated on the antero-lateral aspect of each ankle is a recent 2 cm. transverse incision into the subcutaneous tissue.

There is an old well healed 8 cm. McBurney abdominal incision. Over the lumbar spine in the midline is an old, well healed 15 cm. scar. Situated on the upper antero-lateral aspect of the right thigh is an old, well healed 8 cm. scar.

MISSILE WOUNDS:

1. There is a large irregular defect of the scalp and skull on the right involving chiefly the parietal bone but extending somewhat into the temporal and occipital regions. In this region there is an actual absence of scalp and bone producing a defect which measures approximately 13 cm. in greatest diameter.

From the irregular margins of the above scalp defect tears extend in stellate fashion into the more or less intact scalp as follows:

- a. From the right inferior temporo-parietal margin anterior to the right ear to a point slightly above the tragus.
- b. From the anterior parietal margin anteriorly on the forehead to approximately 4 cm. above the right orbital ridge.
- c. From the left margin of the main defect across the midline antero-laterally for a distance of approximately 8 cm.
- d. From the same starting point as c. 10 cm. postero-laterally.

Situated in the posterior scalp approximately 2.5 cm. laterally to the right and slightly above the external occipital protuberance is a lacerated wound measuring 15 x 6 mm. In the underlying bone is a corresponding wound through the skull which exhibits beveling of the margins of the bone when viewed from the inner aspect of the skull.

Clearly visible in the above described large skull defect and exuding from it is lacerated brain tissue which on close inspection proves to represent the major portion of the right cerebral hemisphere. At this point it is noted that the falx cerebri is extensively lacerated with disruption of the superior sagittal sinus.

Upon reflecting the scalp multiple complete fracture lines are seen to radiate from both the large defect at the vertex and the smaller wound at the occiput. These vary greatly in length and direction, the longest measuring approximately 19 cm. These result in the production of numerous fragments which vary in size from a few millimeters to 10 cm. in greatest diameter.

The complexity of these fractures and the fragments thus produced tax. satisfactory verbal description and are better appreciated in photographs and roentgenograms which are prepared.

The brain is removed and preserved for further study following formalin fixation.

Received as separate specimens from Dallas, Texas are three fragments of skull bone which in aggregate roughly approximate the dimensions of the large defect described above. At one angle of the largest of these fragments is a portion of the perimeter of a roughly circular wound presumably of exit which exhibits beveling of the outer aspect of the bone and is estimated to measure approximately 2.5 to 3.0 cm. in diameter. Roentgenograms of this fragment reveal minute particles of metal in the bone at this margin. Roentgenograms of the skull reveal multiple minute metallic fragments along a line corresponding with a line joining the above described small occipital wound and the right supra-orbital ridge. From the surface of the disrupted right cerebral cortex two small irregularly shaped fragments of metal are recovered. These measure 7 x 2 mm. and 3 x 1 mm. These are placed in the custody of Agents Francis X. O'Neill, Jr. and James W. Sibert, of the Federal Bureau of Investigation, who executed a receipt therefor (attached).

2. The second wound presumably of entry is that described above in the upper right posterior thorax. Beneath the skin there is ecchymosis of subcutaneous tissue and musculature. The missile path through the fascia and musculature cannot be easily probed. The wound presumably of exit was that described by Dr. Malcolm Perry of Dallas in the low anterior cervical region. When observed by Dr. Perry the wound measured "a few millimeters in diameter", however it was extended as a tracheostomy incision and thus its character is distorted at the time of autopsy. However, there is considerable ecchymosis of the strap muscles of the right side of the neck and of the fascia about the trachea adjacent to the line of the tracheostomy wound. The third point of reference in connecting

these two wounds is in the apex (supra-clavicular portion) of the right pleural cavity. In this region there is contusion of the parietal pleura and of the extreme apical portion of the right upper lobe of the lung. In both instances the diameter of contusion and ecchymosis at the point of maximal involvement measures 5 cm. Both the visceral and parietal pleura are intact overlying these areas of trauma.

INCISIONS: The scalp wounds are extended in the coronal plane to examine the cranial content and the customary (Y) shaped incision is used to examine the body cavities.

THORACIC CAVITY: The bony cage is unremarkable. The thoracic organs are in their normal positions and relationships and there is no increase in free pleural fluid. The above described area of contusion in the apical portion of the right pleural cavity is noted.

LUNGS: The lungs are of essentially similar appearance the right weighing 320 Gm., the left 290 Gm. The lungs are well aerated with smooth glistening pleural surfaces and gray-pink color. A 5 cm. diameter area of purplish red discoloration and increased firmness to palpation is situated in the apical portion of the right upper lobe. This corresponds to the similar area described in the overlying parietal pleura. Incision in this region reveals recent hemorrhage into pulmonary parenchyma.

HEART: The pericardial cavity is smooth walled and contains approximately 10 cc. of straw-colored fluid. The heart is of essentially normal external contour and weighs 350 Gm. The pulmonary artery is opened in situ and no abnormalities are noted. The cardiac chambers contain moderate amounts of postmortem clotted blood. There are no gross abnormalities of the leaflets of any of the cardiac valves. The following are the circumferences of the cardiac valves: aortic 7.5 cm., pulmonic 7 cm., tricuspid 12 cm., mitral 11 cm. The myocardium is firm and reddish brown. The left ventricular myocardium averages 1.2 cm. in thickness, the right ventricular myocardium 0.4 cm. The coronary arteries are dissected and are of normal distribution and smooth walled and elastic throughout.

ABDOMINAL CAVITY: The abdominal organs are in their normal positions and relationships and there is no increase in free peritoneal fluid. The vermiform appendix is surgically absent and there are a few adhesions joining the region of the cecum to the ventral abdominal wall at the above described old abdominal incisional scar.

SKELETAL SYSTEM: Aside from the above described skull wounds there are no significant gross skeletal abnormalities.

PHOTOGRAPHY: Black and white and color photographs depicting significant findings are exposed but not developed. These photographs were placed in the custody of Agent Roy H. Kellerman of the U. S. Secret Service, who executed a receipt therefore (attached).

ROENTGENOGRAMS:

Roentgenograms are made of the entire body and of the separately submitted three fragments of skull bone. These are developed and were placed in the custody of Agent Roy H. Kellerman of the U. S. Secret Service, who executed a receipt therefor (attached).

SUMMARY:


Based on the above observations it is our opinion that the deceased died as a result of two perforating gunshot wounds inflicted by high velocity projectiles fired by a person or persons unknown. The projectiles were fired from a point behind and somewhat above the level of the deceased. The observations and available information do not permit a satisfactory estimate as to the sequence of the two wounds.

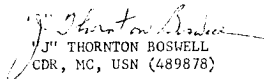
The fatal missile entered the skull above and to the right of the external occipital protuberance. A portion of the projectile traversed the cranial cavity in a posterior-anterior direction (see lateral skull roentgenograms) depositing minute particles along its path. A portion of the projectile made its exit through the parietal bone on the right carrying with it portions of cerebrum, skull and scalp. The two wounds of the skull combined with the force of the missile produced extensive fragmentation of the skull, laceration of the superior saggital sinus, and of the right cerebral hemisphere.


The other missile entered the right superior posterior thorax above the scapula and traversed the soft tissues of the supra-scapular and the supra-clavicular portions of the base of the right side of the neck. This missile produced contusions of the right apical parietal pleura and of the apical portion of the right upper lobe of the lung. The missile contused the strap muscles of the right side of the neck, damaged the trachea and made its exit through the anterior surface of the neck. As far as can be ascertained this missile struck no bony structures in its path through the body.

In addition, it is our opinion that the wound of the skull produced such extensive damage to the brain as to preclude the possibility of the deceased surviving this injury.

A supplementary report will be submitted following more detailed examination of the brain and of microscopic sections. However, it is not anticipated that these examinations will materially alter the findings.


J. J. HUMES
CDR, MC, USN (497831)


"J" THORNTON BOSWELL
CDR, MC, USN (489878)


PIERRE A. FINCK
LT COL, MC, USA
(04-043-322)

JFK EXHIBIT F-43

SUPPLEMENTARY REPORT OF AUTOPSY NUMBER A63-272
 PRESIDENT JOHN F. KENNEDY

✓ 6/63

ANATOMICAL DETERMINATION REPORT

No. A63-272

GROSS DESCRIPTION OF BRAIN:

Following formalin fixation the brain weighs 1500 gms. The right cerebral hemisphere is found to be markedly disrupted. There is a longitudinal laceration of the right hemisphere which is para-sagittal in position approximately 2.5 cm. to the right of the of the midline which extends from the tip of the occipital lobe posteriorly to the tip of the frontal lobe anteriorly. The base of the laceration is situated approximately 4.5 cm. below the vertex in the white matter. There is considerable loss of cortical substance above the base of the laceration, particularly in the parietal lobe. The margins of this laceration are at all points jagged and irregular, with additional lacerations extending in varying directions and for varying distances from the main laceration. In addition, there is a laceration of the corpus callosum extending from the genu to the tail. Exposed in this latter laceration are the interiors of the right lateral and third ventricles.

When viewed from the vertex the left cerebral hemisphere is intact. There is marked engorgement of meningeal blood vessels of the left temporal and frontal regions with considerable associated sub-arachnoid hemorrhage. The gyri and sulci over the left hemisphere are of essentially normal size and distribution. Those on the right are too fragmented and distorted for satisfactory description.

When viewed from the basilar aspect the disruption of the right cortex is again obvious. There is a longitudinal laceration of the mid-brain through the floor of the third ventricle just behind the optic chiasm and the mammillary bodies. This laceration partially communicates with an oblique 1.5 cm. tear through the left cerebral peduncle. There are irregular superficial lacerations over the basilar aspects of the left temporal and frontal lobes.

In the interest of preserving the specimen coronal sections are not made. The following sections are taken for microscopic examination:

- a. From the margin of the laceration in the right parietal lobe.
- b. From the margin of the laceration in the corpus callosum.
- c. From the anterior portion of the laceration in the right frontal lobe.
- d. From the contused left fronto-parietal cortex.
- e. From the line of transection of the spinal cord.
- f. From the right cerebellar cortex.
- g. From the superficial laceration of the basilar aspect of the left temporal lobe.

During the course of this examination seven (7) black and white and six (6) color 4x5 inch negatives are exposed but not developed (the cassettes containing these negatives have been delivered by hand to Rear Admiral George W. Burkley, MC, USN, White House Physician).

MICROSCOPIC EXAMINATION:

BRAINE:

Multiple sections from representative areas as noted above are examined. All sections are essentially similar and show extensive disruption of brain tissue with associated hemorrhage. In none of the sections examined are there significant abnormalities other than those directly related to the recent trauma.

HEART:

Sections show a moderate amount of sub-epicardial fat. The coronary arteries, myocardial fibers, and endocardium are unremarkable.

LUNGS:

Sections through the grossly described area of contusion in the right upper lobe exhibit disruption of alveolar walls and recent hemorrhage into alveoli. Sections are otherwise essentially unremarkable.

LIVER:

Sections show the normal hepatic architecture to be well preserved. The parenchymal cells exhibit markedly granular cytoplasm indicating high glycogen content which is characteristic of the "liver biopsy pattern" of sudden death.

SPLEEN:

Sections show no significant abnormalities.

KIDNEYS:

Sections show no significant abnormalities aside from dilatation and engorgement of blood vessels of all calibers.

SKIN WOUNDS:

Sections through the wounds in the occipital and upper right posterior thoracic regions are essentially similar. In each there is loss of continuity of the epidermis with coagulation necrosis of the tissues at the wound margins. The scalp wound exhibits several small fragments of bone at its margins in the subcutaneous tissue.

FINAL SUMMARY:

This supplementary report covers in more detail the extensive degree of cerebral trauma in this case. However neither this portion of the examination nor the microscopic examinations alter the previously submitted report or add significant details to the cause of death.


J. J. Humes
J. J. HUMES
CDR, MC, USN, 497831

5/24/48

6 December 1963

From: Commanding Officer, U. S. Naval Medical School
To: The White House Physician
Via: Commanding Officer, National Naval Medical Center
Subj: Supplementary report of Naval Medical School autopsy No. A63-272,
John F. Kennedy; forwarding of

1. All copies of the above subject final supplementary report are forwarded herewith.

J. H. STOVER, JR. 

6 December 1963

FIRST ENDORSEMENT

From: Commanding Officer, National Naval Medical Center
To: The White House Physician

1. Forwarded.

C. B. GALLOWAY

JFK EXHIBIT F-44

AUTOPSY DESCRIPTIVE SHEET

AUTOPSY

NAME # A-63 # 272 DATE 11-22-63 HR. STARTED _____ HR. COMPLETED _____

NAME: _____ RANK/RATE _____

DATE/HOUR EXPIRED: _____ WARD _____ DIAGNOSIS _____

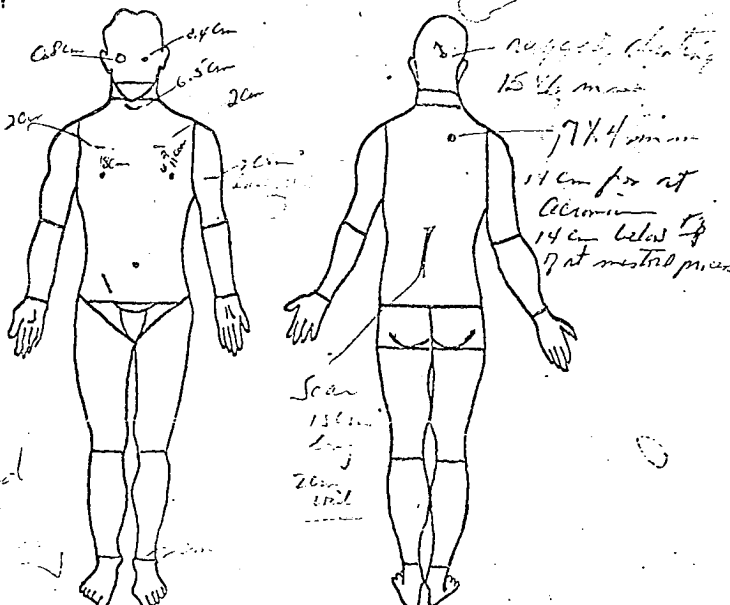
PHYSICAL DESCRIPTION: RACE: _____ Obtain following on babies only:

Height _____ in. Weight _____ lb. Hair _____ Color _____
 Crown-rump _____ in. Crown-heel _____ in.
 Color eyes _____ Pupil: Rt _____ mm, Lb. _____ mm Circumference: Head _____ in. Chest _____ in.
 Abd. _____ in.
 WEIGHTS: (Grams, unless otherwise specified)

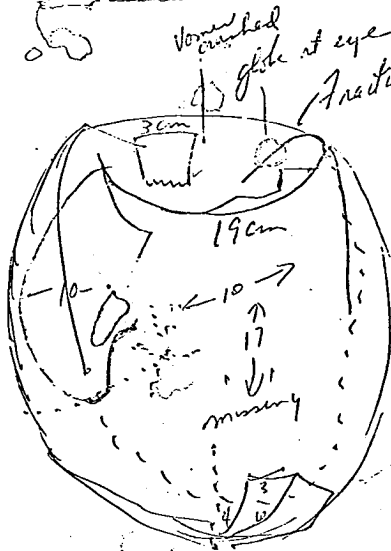
LUNG, RT. 320 KIDNEY, RT. 1395 ADRENALS, RT. _____
 LUNG, LT. 290 KIDNEY, LT. 140 ADRENALS, LT. _____
 BRAIN _____ LIVER 150 PANCREAS _____
 SPLEEN 90 HEART 50 THYROID _____
 THYMUS _____ TESTIS _____ OVARY _____

HEART MEASUREMENTS: A 7.5 cm. P 7 cm. T 1.2 cm. M 16 cm.
 LVM 1.5 cm. RVW .4 cm.

NOTES:



Pathologist _____



• Help from sagittal
• from the
• Canal sutures.



Mr. KLEIN. Do you recognize these reports, Doctor?

Dr. BADEN. Yes. These are copies of reports that the panel had opportunity to see and examine. The panel members then had the opportunity to question the persons who prepared the reports.

Mr. KLEIN. Who prepared those reports?

Dr. BADEN. The autopsy reports of President Kennedy were prepared by Dr. Humes and Dr. Boswell, who were the autopsy physicians.

Mr. KLEIN. When were they prepared?

Dr. BADEN. They were prepared during the course of, and in the 2 days following, the performance of the autopsy with the written portions prepared the day following the autopsy.

Mr. KLEIN. When was the supplementary report prepared?

Dr. BADEN. The supplementary report was prepared 2 weeks later and describes the brain after fixation in formaldehyde, which is a customary way of preparing the brain prior to further examination, and also describes the findings on microscopic examination of various tissues of the President. These two types of study do take time in the normal course of an autopsy and such reports are prepared some time after the initial autopsy.

Mr. KLEIN. With respect to the wounds of the upper right back and the front of the neck, what did the autopsy report conclude?

Dr. BADEN. The autopsy report concludes that there was a gunshot perforation of entrance in the right upper back and that the exit wound was in the front of the neck.

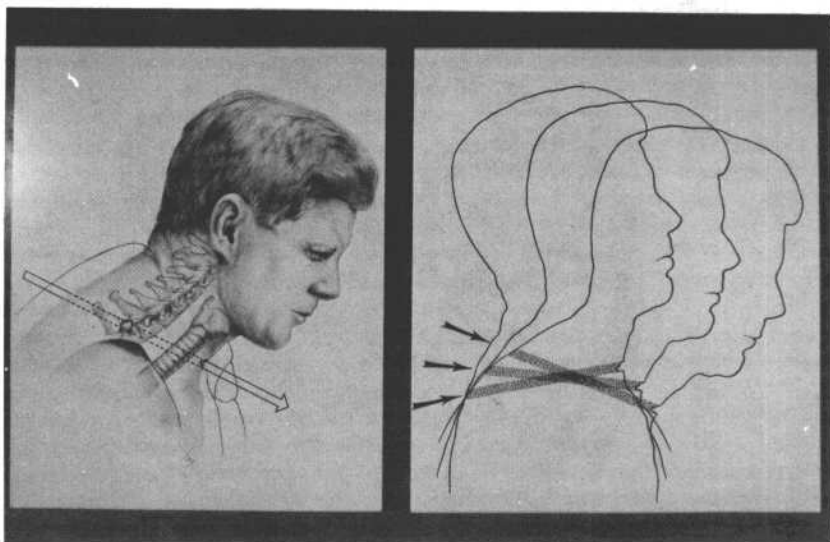
Mr. KLEIN. Doctor, on the basis of the foregoing evidence, photos and X-rays taken at the autopsy, the examination of the President's clothing, the reports of radiologists, interviews of the surgeons who attended the President at Parkland Hospital, and the autopsy report, did the panel unanimously conclude that a bullet entered the upper right back of the President and exited from the front of his neck?

Dr. BADEN. Every member of the panel so concluded.

Mr. KLEIN. Mr. Chairman, at this time I would ask that the drawing marked JFK F-46 be received as a committee exhibit.

Chairman STOKES. Without objection, it may be received and entered into the record at this point.

[The above-mentioned document, JFK exhibit F-46, a drawing, follows:]



JFK EXHIBIT F-46

Mr. KLEIN. Doctor, do you recognize that drawing?

Dr. BADEN. Yes, I do.

Mr. KLEIN. What does that show?

Dr. BADEN. This is a drawing prepared by Miss Dox with the medical panel of the upper portion of the President showing the track that the bullet took through the back, exiting the neck adjacent to the spine, and through the windpipe (or trachea) in the neck; it shows the direction of the bullet path in the body. This path can be produced by various bullet trajectories, depending on the position of the President at the time the missile struck. On your right, there are three positions of the head of the President all showing the same bullet track and direction within the body, going from the back to the exit in the neck, that could be inflicted by a bullet traveling upward, approximately horizontally, or downward.

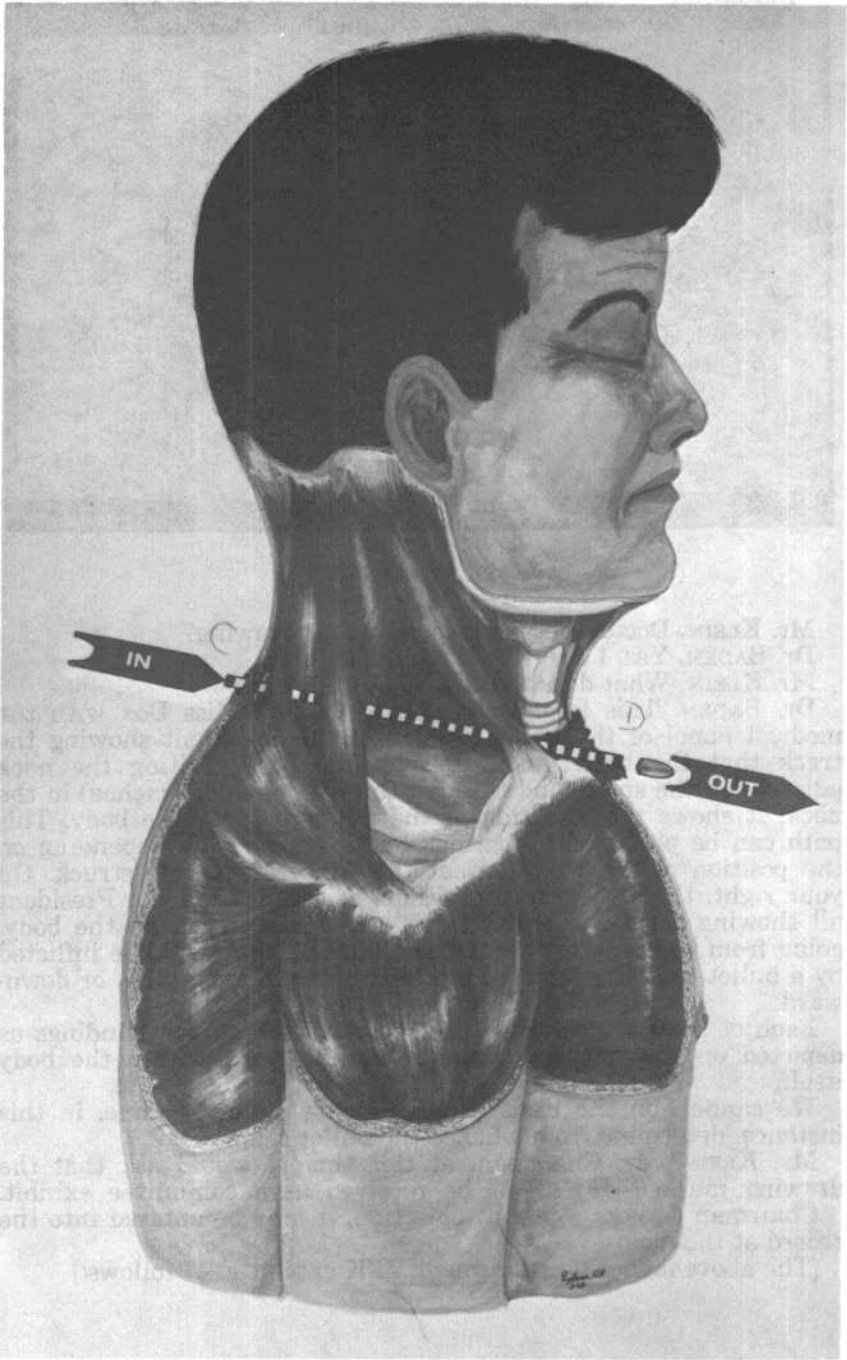Each of these trajectories could produce the autopsy findings as depicted on the left and cause a similar track within the body itself.

We cannot, on the basis of the autopsy findings alone, in this instance, determine from whence the bullet came.

Mr. KLEIN. Mr. Chairman, at this time, I would ask that the drawing marked JFK F-47 be received as a committee exhibit.

Chairman STOKES. Without objection, it may be entered into the record at this point.

[The above-mentioned document, JFK exhibit F-47 follows:]



JFK EXHIBIT F-47

Mr. KLEIN. Do you recognize that drawing, Doctor?

Dr. BADEN. Yes, sir; I recognize this as a drawing made for the Warren Commission depicting the same track from back to front neck region that we have been describing.

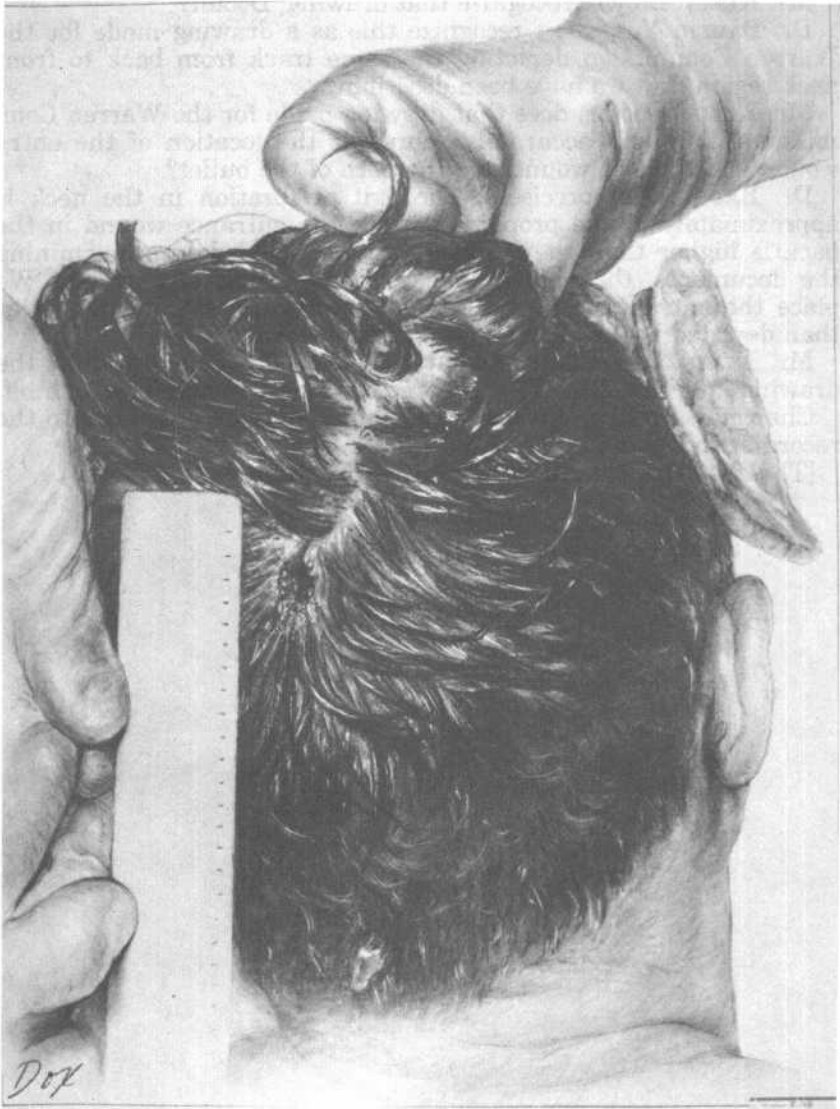Mr. KLEIN. Doctor, does that drawing made for the Warren Commission fairly and accurately represent the location of the entry wound and the exit wound and the path of the bullet?

Dr. BADEN. Not precisely. The exit perforation in the neck is approximately at the proper area, but the entrance wound in the back is higher than the medical panel concluded from examining the documents, the photographs as to the point of entrance. We place the entrance perforation a bit lower, almost 2 inches lower than depicted in the Warren Commission exhibit.

Mr. KLEIN. Mr. Chairman, at this time, I would ask that the drawing marked JFK F-48 be received as a committee exhibit.

Chairman STOKES. Without objection, it may be entered into the record at this point.

[The above-mentioned document, JFK exhibit F-48, follows:]



JFK EXHIBIT F-48

Mr. KLEIN. Do you recognize that drawing, Doctor?

Dr. BADEN. Yes, sir.

Mr. KLEIN. What does that drawing depict?

Dr. BADEN. This is a drawing made from photographs taken at the time of the autopsy showing the back of the President's head and showing a ruler adjacent to an area of discoloration in the cowlick area of the back of the head of the scalp, which the panel determined was an entrance perforation, an entrance bullet perforation; this also shows portions of fractures of the skull of the

President caused by this gunshot wound and a fragment of dried tissue near the hairline of the President.

Mr. KLEIN. Doctor, does this drawing fairly and accurately represent the location of the wound high in the back of the President's head?


Dr. BADEN. Yes, it does, in the unanimous opinion of all of the panel members.

Mr. KLEIN. Mr. Chairman, I would ask that the photographs marked JFK F-49A and F-49B and the blowups marked JFK F-50 and F-51 be received as committee exhibits.

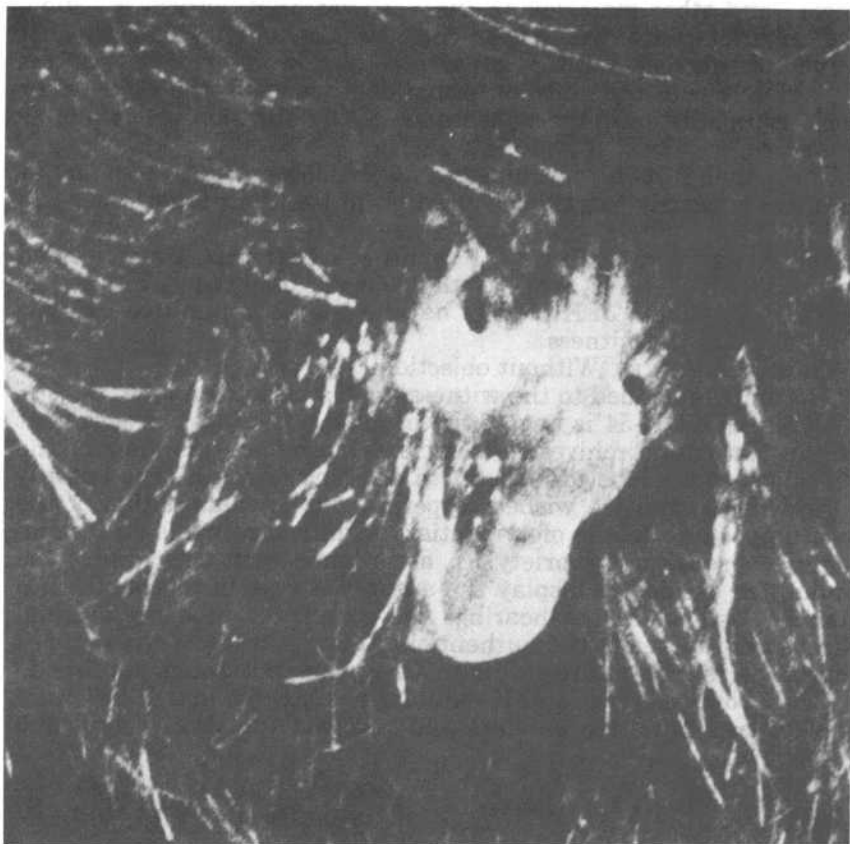Chairman STOKES. Without objection, they may be entered into the record at this point.

[JFK exhibits F-49A and F-49B are 8 by 10 photographs derived from the original autopsy photographs and depict posterior views of the head of the President. In deciding to release the autopsy photographs, the committee wished to permit public examination of the most important details of evidentiary significance while still maintaining a sense of propriety. In accordance with this desire, the committee decided to display the autopsy photographs to the public in either drawings that represent large areas of the President's body as seen in the photograph or closely cropped photographs that depict the most important areas of evidentiary concern. The committee used photographs such as JFK F-49A and F-49B in the hearings only to verify the authenticity and accuracy of the drawings and closely cropped photographs; these photographs are not being published. The original autopsy photographs and committee copies are in the custody of the National Archives.]

[The above-mentioned documents, JFK F-50, and F-51, follow:]



JFK EXHIBIT F-50



JFK EXHIBIT F-51

Dr. BADEN. Yes, sir; I have the 8 by 10 photographs.

Mr. KLEIN. Do you recognize those photographs and those blowups?

Dr. BADEN. Yes, Mr. Klein.

Mr. KLEIN. Would you tell us what they are?

Dr. BADEN. The two photographs I have, 8 by 10 glossy prints, have been prepared from the original photographs in the Archives and show enlargement of the perforation in the cowlick area of the scalp, which is represented on your extreme right in this area; the detail in the photograph is much superior to the blowup detail.

Also depicted in the center is the area in the lower back of the head which I referred to as dry tissue. This is depicted in the middle photograph. These are both enlargements of the actual photographs taken prior to the autopsy of the President.

Mr. KLEIN. Doctor, using those blowups, would you please explain to the committee what the panel learned from those photographs?

Dr. BADEN. The panel did learn and conclude from the photographs and close examination under magnification of the transpar-

encies, and other materials in the Archives, that without question, the superior more area under consideration is a typical gunshot wound of entrance and that it corresponded in many of its features very closely with the gunshot wound of entrance in the right upper back, especially as to the appearance of the abrasion collar and as to its size.

The panel further concluded that the lower more area under question is clearly extraneous dried brain tissue on top of the scalp hair.

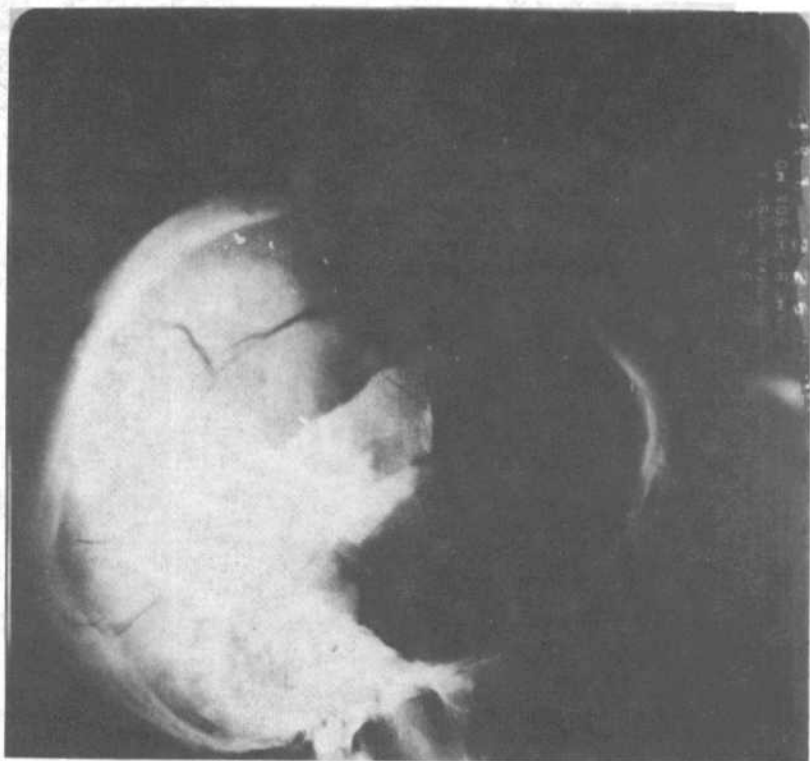
Mr. KLEIN. Mr. Chairman, I would ask that this X-ray deemed marked JFK F-54 as well as the blowups marked "JFK F-52," "JFK F-53," and "JFK F-297" be received as committee exhibits and shown to the witness.

Chairman STOKES. Without objection.

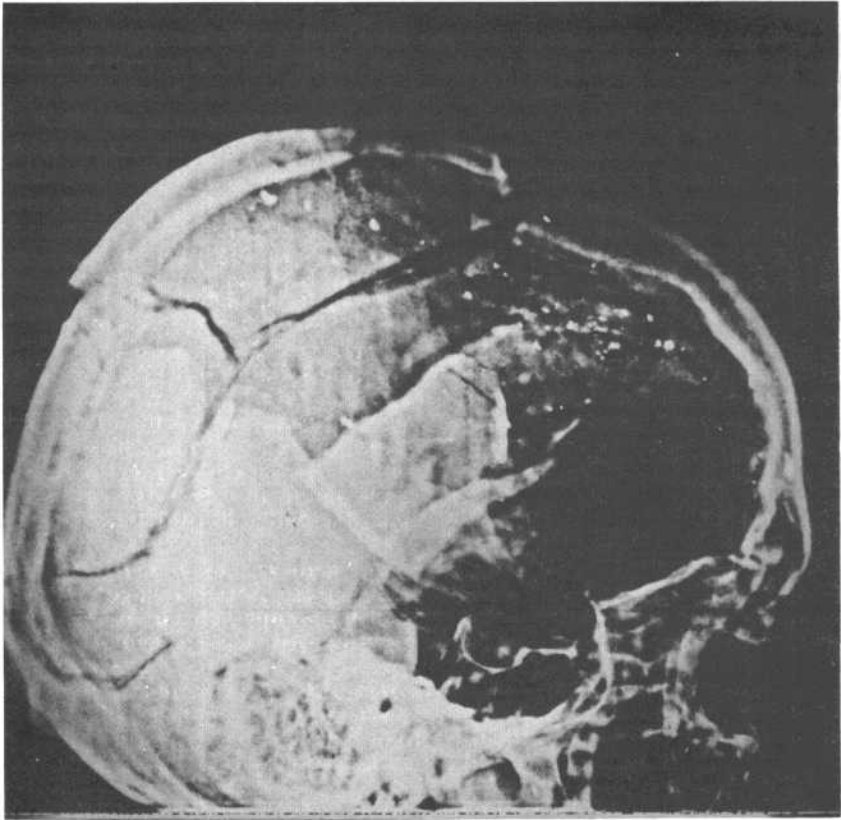
[Documents handed to the witness for his inspection.]

[JFK exhibit F-54 is one of the original 14 autopsy X-rays kept at the National Archives. It depicts a lateral or side view of the President and is labeled "No. 2." In deciding to release the autopsy X-rays the committee wished to permit public examination of the most important details of evidentiary significance while still maintaining a sense of propriety. In accordance with this desire, the committee decided to display the autopsy X-rays to the public in a cropped fashion. In the hearings the committee used the original X-rays only to verify the authenticity and accuracy of the cropped counterparts; the entire original X-rays are not being published.]

[The above-referred-to JFK exhibits F-52, F-53, and F-297 were marked as committee exhibits and received into the record, and follow:]

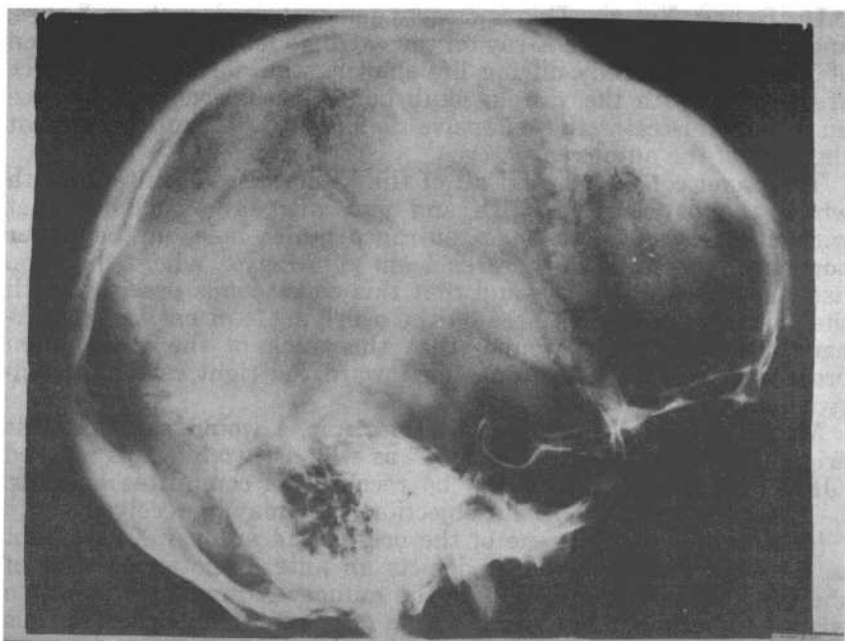


JFK EXHIBIT F-52



RIGHT SIDE DOWN HEAD X-RAY - ENHANCED IMAGE - 11 X 11 BLOCK
MAPPING 255:0.00 0:5.11 WEIGHT = 0.79
SCALE 414 MICRONS PER PIXEL

JFK EXHIBIT F-53



JFK EXHIBIT F-297

Mr. KLEIN. Do you recognize those X-rays and those blowups?

Dr. BADEN. Yes, I do.

This is X-ray labeled "No. 2" by the tag applied by Dr. Ebersole and identified to the panel members by Dr. Ebersole as an X-ray he took at the time of the autopsy of President Kennedy; it shows a side view of the President's head and is preserved in the Archives. This is an enlarged copy of that specific X-ray showing a side view of the skull of the President with the back of the head to your left, the front of the head to your right. Because of the difficulty interpreting some of the subtle features on the X-ray, the X-rays were further examined using enhancement techniques to increase the image contrast. This is a computerized enhancement on your right of the same X-ray showing the same structures but bringing out some of the details of the X-ray more clearly by the enhancement techniques.

Mr. KLEIN. What did the panel learn from those X-rays?

Dr. BADEN. The panel learned from these X-rays that there was extensive fracturing of the bones of the skull of the President as manifested by these various lines and irregularities, that there was displacement of some bony fragments as a result of this explosive-type injury to the skull as seen on the X-ray, and that there are many small white areas in the X-ray film that are metallic fragments resulting from a bullet having passed through the skull and fragmenting to some small degree.

Mr. KLEIN. Are those X-rays consistent with a bullet having entered the President's head high on top of the head and passed through?

Dr. BADEN. Yes sir. This is clearly demonstrated in these X-rays, and as comparison, the X-ray on the extreme left is an X-ray taken of President Kennedy during life showing the normal appearance of the skull with the various skull bones in their normal appearance and illustrates the extensive damage of the skull present at the time of the autopsy.

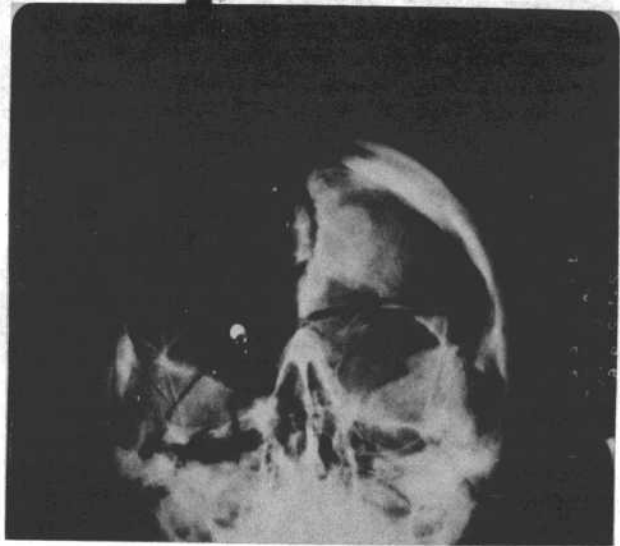The panel concluded, and all of the radiologist consultants with whom the panel spoke with and met with, all concluded that without question there is an entrance bullet hole on the upper portion of the skull at the area I am pointing to, where the bone itself has been displaced, and that this corresponds precisely with the point in the cowlick area on the overlying skin has the appearance of an entrance wound, that the track of the bullet then proceeded from back to front and toward the right causing extensive damage to the head.

Mr. KLEIN. Mr. Chairman, at this time, I would ask that this original X-ray marked "JFK F-57" as well as two blowups marked "JFK F-55" and "JFK F-56" be received as committee exhibits.

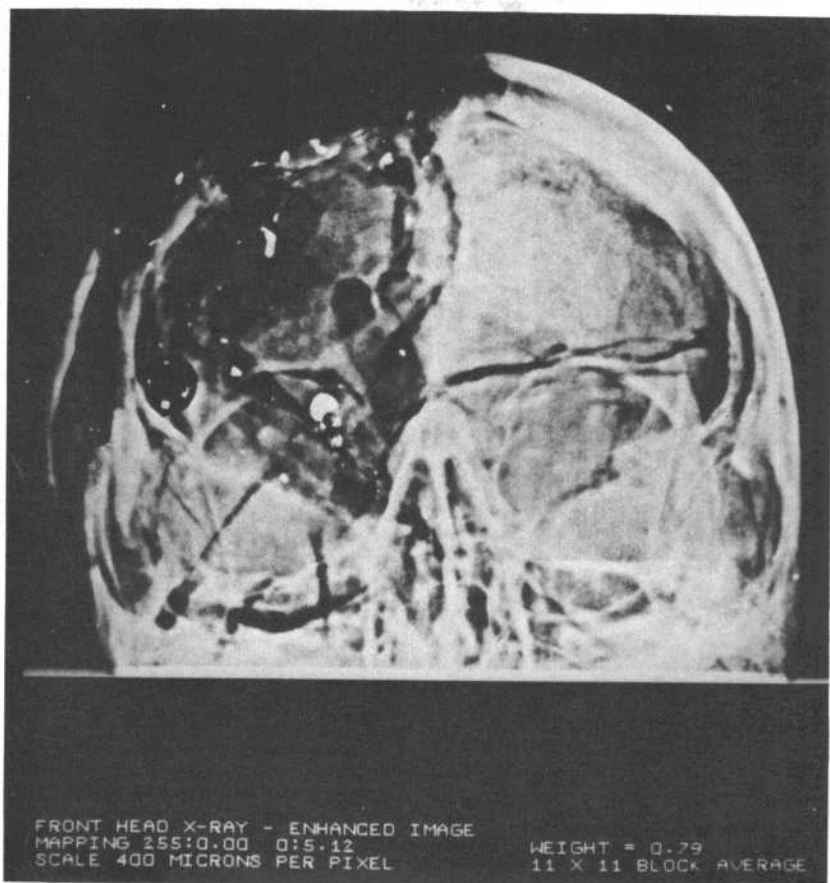
Chairman STOKES. Without objection, they may be received.

[JFK exhibit F-57 is one of the original 14 autopsy X-rays kept at the National Archives. It depicts an anterior-posterior view of the skull. In deciding to release the autopsy X-rays the committee wished to permit public examination of the most important details of evidentiary significance while still maintaining a sense of propriety. In accordance with this desire, the committee decided to display the autopsy X-rays to the public in a cropped fashion. In the hearings the committee used the original X-rays only to verify the authenticity and accuracy of the cropped counterparts; the entire original X-rays are not being published.]

[The above-referred-to exhibits "JFK F-55" and "JFK F-56" were marked committee exhibits and received into the record and follow:]



JFK EXHIBIT F-55



JFK EXHIBIT F-56

Dr. BADEN. For orientation, this is the back of the skull, front of the skull, the eye area, pituitary gland, the ear bones.

Mr. Klein, what I have just been given is an X-ray from the Archives viewed by the panel at the Archives with the label in red "No. 1" affixed.

Mr. KLEIN. Would you briefly tell us, using the blowups, what the panel learned from these X-rays?

Dr. BADEN. Yes, this is an antero-posterior view of the skull—that is, taken with the back of the head directly against the X-ray film. These are true enlargements of portions of those X-rays.

Mr. KLEIN. Are these X-rays consistent with a bullet having passed through the President's head?

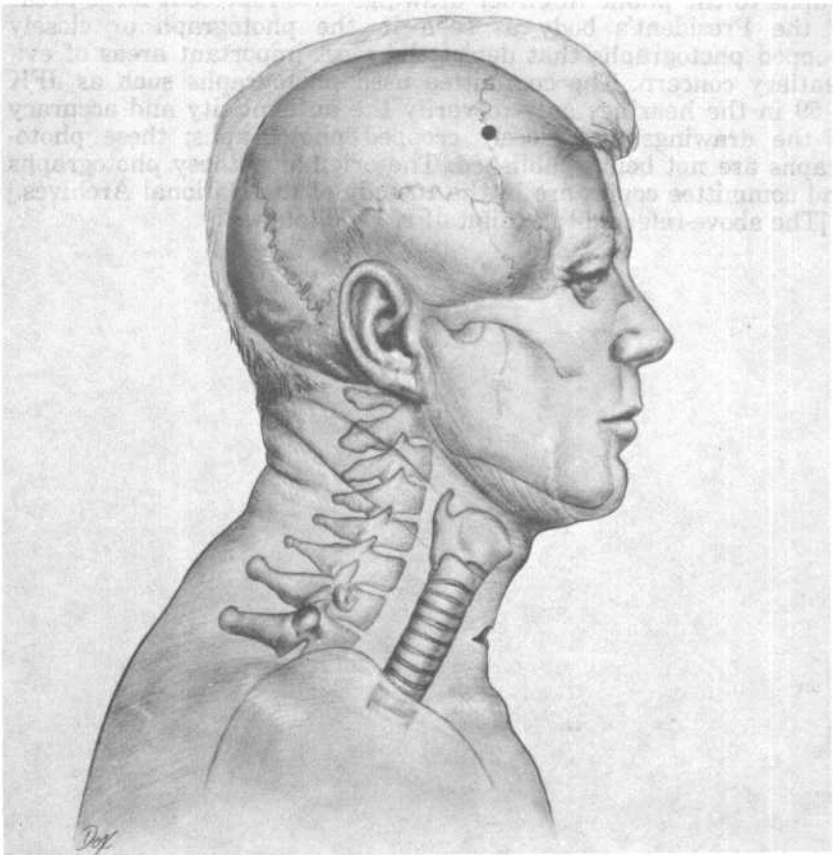
Dr. BADEN. Yes; there is extensive damage to the right side of the skull area, shown more clearly in the enhancement of the X-

ray, and there are extensive fracture lines radiating from the point of entrance marked by this relatively large metal fragment and the X-ray lines extending from it. This corresponds precisely to the point of entrance beneath the cowlick area and shows the extensive loss of bone at that area.

Mr. KLEIN. Mr. Chairman, at this time I ask that the drawing marked "JFK F-58" be received as an exhibit and shown to the witness.

Chairman STOKES. Without objection, it may be received at this point.

[The above-referred-to exhibit "JFK F-58" follows:]



JFK EXHIBIT F-58

Mr. KLEIN. Doctor, do you recognize that drawing?


Dr. BADEN. Yes; this is a drawing prepared with the panel and Miss Dox showing a side view of the President's skull and showing the point that the panel agreed was the exit point for the gunshot wound that entered the back of the head; this exit perforation is on the right front side of the head of the President.

Mr. KLEIN. Mr. Chairman, at this time, I would ask that this photograph and the blowup marked "JFK F-59" and "JFK F-60" be received as committee exhibits and shown to the witness.

Chairman STOKES. Without objection, they may be received at this point.

[JFK exhibit F-59 is an 8 by 10 photograph derived from one of the original autopsy photographs and depicts the area of bone injury on the right side of the head. In deciding to release the autopsy photographs, the committee wished to permit public examination of the most important details of evidentiary significance while still maintaining a sense of propriety. In accordance with this desire, the committee decided to display the autopsy photographs to the public in either drawings that represent large areas of the President's body as seen in the photograph or closely cropped photographs that depict the most important areas of evidentiary concern. The committee used photographs such as JFK F-59 in the hearings only to verify the authenticity and accuracy of the drawings and closely cropped photographs; these photographs are not being published. The original autopsy photographs and committee copies are in the custody of the National Archives.]

[The above-referred-to exhibit JFK F-60 follows:]



JFK EXHIBIT F-60

Mr. KLEIN. Doctor, do you recognize that photograph and that blowup?

Dr. BADEN. Yes; this is a detail of one of the autopsy photographs, in fact the only photograph that shows any internal structures of the President at the time of autopsy as opposed to all of the other photographs which are of the outside of the body. This photograph shows the bullet exit area on the right side of the head and is seen in better detail and sharper on the photograph than in the blowup. The photograph shows the front right part of the skull

of the President and the semicircular defect that I am pointing to corresponds with the black dot present on the previous exhibit. This is a portion of a gunshot wound of exit as determined by the panel because of the beveling of the outer layer of bone visible in the photographs, which is also described in the autopsy report. Beveling refers to the breaking away of bone in a concave pattern as when a BB goes through plate glass causing a concavity in the glass in the direction in which the BB is proceeding.

This also happens when a bullet enters and exits skull bone and other bones. It is the conclusion of the panel that this is unquestionably an exit perforation.

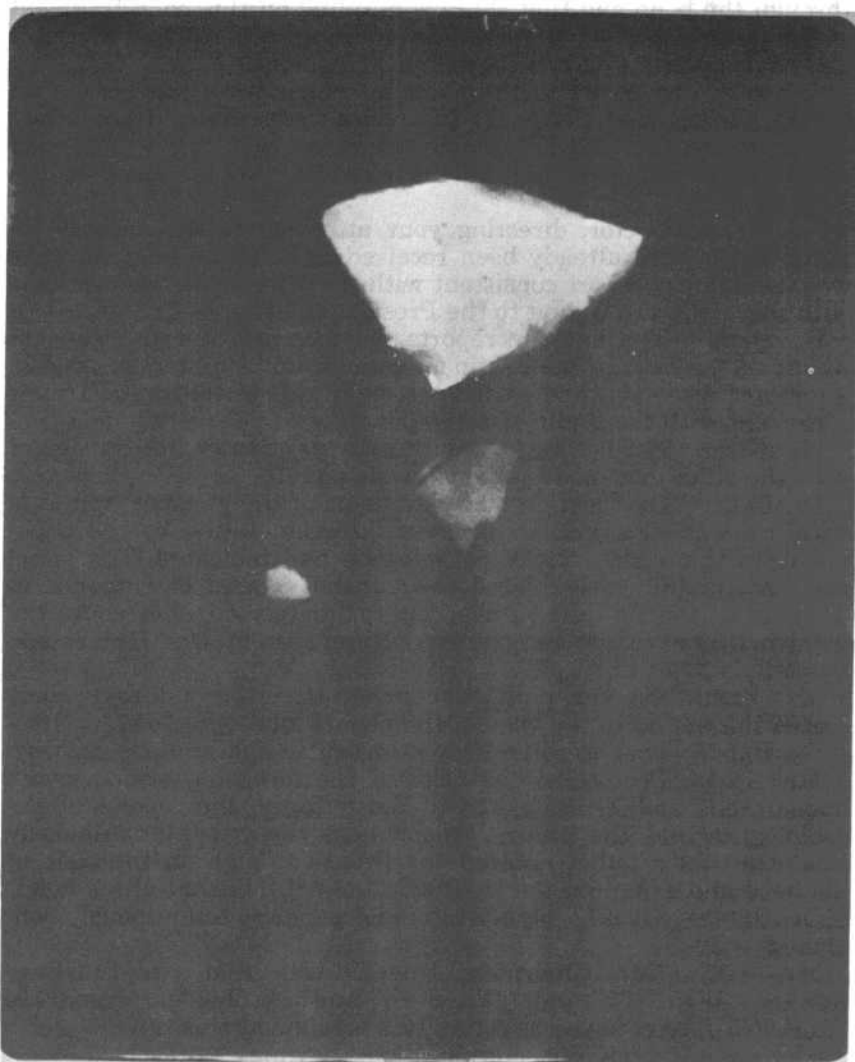
Mr. KLEIN. Does the beveling allow you to make a determination whether it is an entry or exit perforation?

Dr. BADEN. Yes. When a bullet strikes bone, especially flat bone such as the skull, the entrance into the bone is sharp and the exit from the bone is beveled. The bone breaks and bevels in the direction that the bullet is going and we are then able to tell as here, because the beveling is on the outside of the skull, on the right side, that the bullet traveled from within the skull to the outside causing this characteristic change in the bone where the bullet exited.

Mr. KLEIN. Mr. Chairman, at this time, I would ask that the blowup marked "JFK F-64" be received as a committee exhibit.

Chairman. STOKES. Without objection, it may be received at this point.

[The above-referred-to exhibit JFK F-64 follows:]



JFK EXHIBIT F-64

Mr. KLEIN. Doctor, do you recognize that blowup?

Dr. BADEN. Yes sir, this is a blowup of one of the X-rays, one of the 14 X-rays kept at the Archives, showing 3 fragments of bone received by Dr. Humes and Dr. Boswell in the autopsy room while they were performing the autopsy on the President, that had been retrieved from the limousine in which the President had been riding. The doctors looked at the bone fragments, took X-rays of the bone fragments, inserted this particular bone fragment against this semicircle and concluded that they matched and fitted together. On this larger triangular fragment there is at one edge metal fragments seen on the X-ray that the panel concluded, and the autopsy physicians concluded, were part of the exit perforation

through the bone and that there is beveling on this bony fragment of the outer aspect of the bone. In addition, a portion of a suture line is also present on one edge of this fragment.

A suture line refers to the point at which two bones join. This suture line assisted the panel in precisely identifying from where the fragment derived. The panel concluded that this was part of the gunshot wound of exit of the right side of the head of the President.

Mr. KLEIN. Doctor, directing your attention to the autopsy reports which have already been received as exhibits, in what ways was the autopsy report consistent with the other evidence available with respect to the wound to the President's head?

Dr. BADEN. The autopsy reports did indicate that the gunshot wound of the head of the President came from behind, proceeded in a forward direction, and exited the right side of the skull. This is consistent with the findings of the panel.

Mr. KLEIN. In what ways was the autopsy report not consistent with the other evidence available to the panel?

Dr. BADEN. The location and placement of the gunshot wound of entrance was significantly different on examination by the panel members than the autopsy pathologists had indicated. The panel members unanimously placed the gunshot wound of entrance in the back of the President's head approximately 4 inches above the point indicated in the autopsy report prepared by Drs. Humes and Boswell.

Mr. KLEIN. So the panel concluded that the autopsy report placed the wound in the back of the head 4 inches too low?

Dr. BADEN. That is correct; as recorded in the original autopsy.

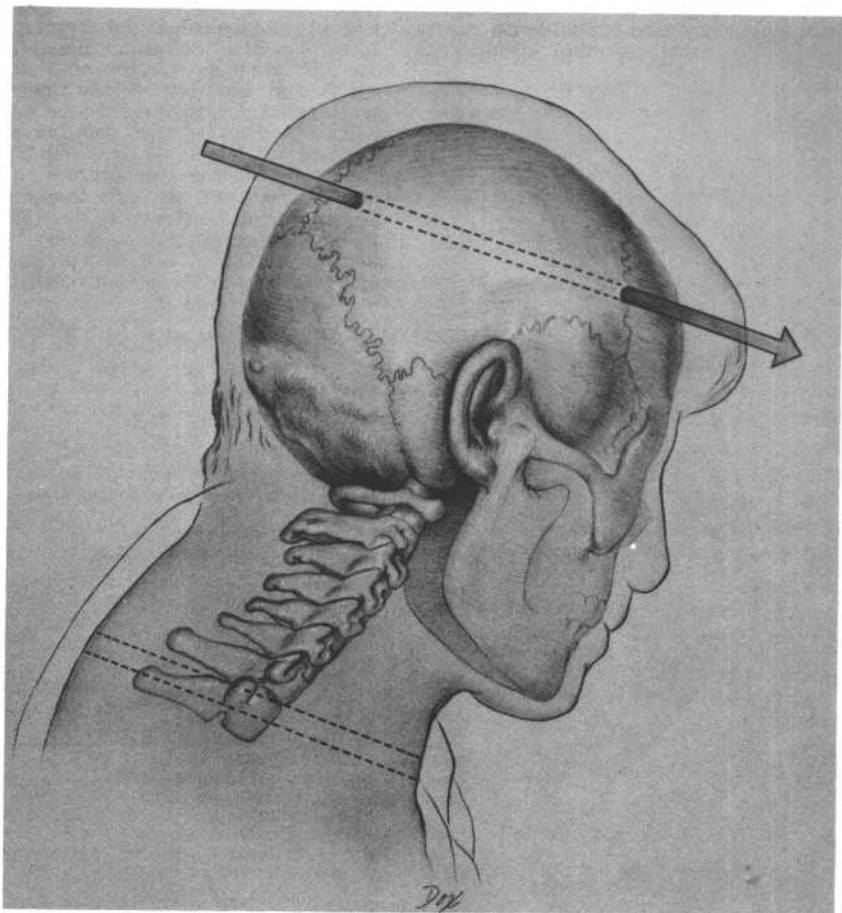
Mr. KLEIN. Doctor, on the basis of the foregoing evidence, the photographs and X-rays taken of the autopsy, the reports of the radiologists and the autopsy report, did the panel unanimously conclude that a bullet entered the President high on the back of his head and exited on the right side toward the front of his head?

Dr. BADEN. All nine members of the panel so unanimously concluded.

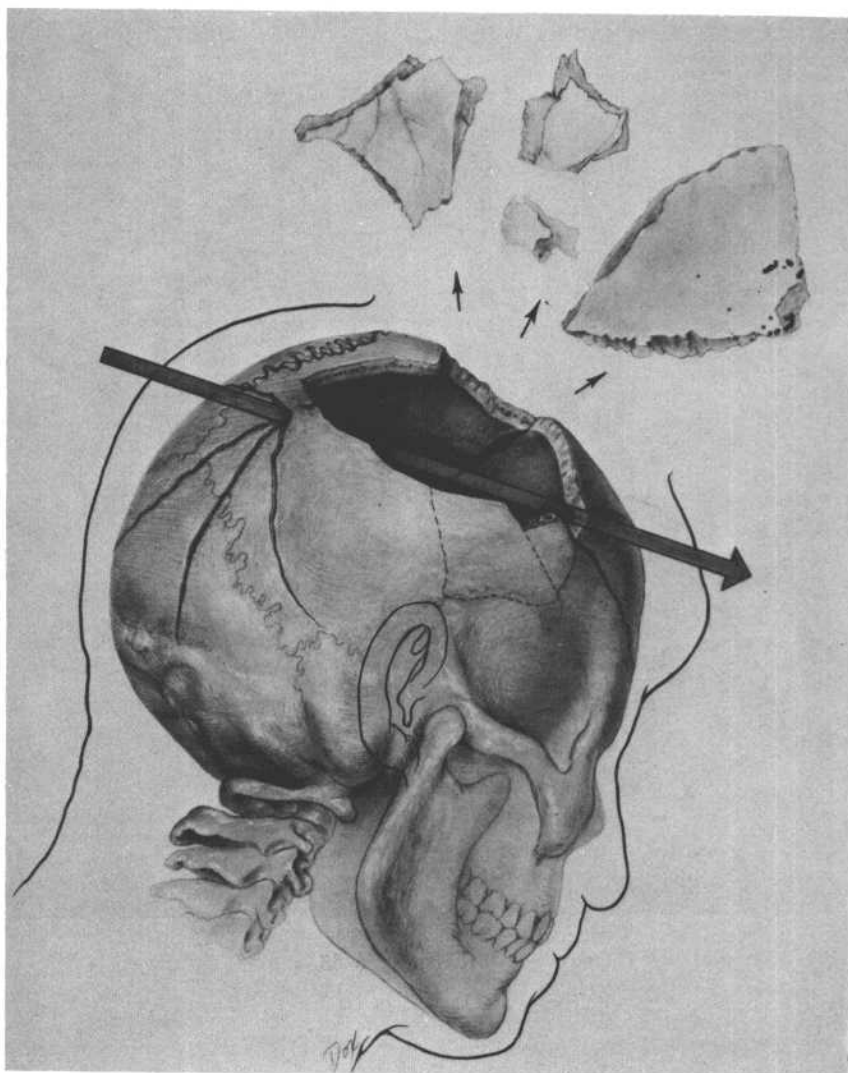
Mr. KLEIN. Mr. Chairman, I would ask that two drawings marked "JFK F-65" and "JFK F-66" and the photograph marked "JFK F-67" be received as committee exhibits at this time.

Chairman STOKES. Without objection, they may be received.


[The above referred to exhibits, "JFK F-65," "JFK F-66," and "JFK F-67" follow:]



JFK EXHIBIT F-65



JFK EXHIBIT F-66



JFK EXHIBIT F-67

Mr. KLEIN. Do you recognize these exhibits, doctor?

Dr. BADEN. Yes, I do.

Mr. KLEIN. What do they depict?

Dr. BADEN. The drawings were prepared with Miss Dox and the members of the panel to illustrate the path of the gunshot wounds that struck the President. The photograph is Zapruder frame 312 and shows the President just before the explosion caused by the head shot.

Mr. KLEIN. Do the diagrams fairly and accurately represent the path of the bullet which entered high on the back of the President's head and exited from the right side of the head toward the front?

Dr. BADEN. Yes, sir. One, the drawing to your right, indicates the path of the bullet entering the right upper head region approximately 1 inch to the right of the midline of the body and approximately 4 inches above a bony prominence in the back of the head, the external occipital protuberance which is depicted here.

This bullet, then, proceeds from back to front exiting in the area of the suture line, that I mentioned earlier, the coronal suture line as depicted on the drawing, causing a semicircular defect in the frontal bone of the skull.

This drawing does indicate that at the time of this injury to the back of the head there already existed in the body a bullet track of the right upper back region going from back to front exiting through the tracheostomy incision in the front of the neck.

The other diagram, the other drawing, is an attempt to illustrate the direction of the gunshot wound and the damage done to the skull, utilizing the X-rays in great measure and the photographs taken at the autopsy procedure. This shows the entrance perforation in the upper posterior right side of the skull, and the bullet path proceeding forward causing extensive fractures of the skull bones on the right and then exiting the right front area.

The four bone fragments illustrated in this diagram are drawn to scale in relation to each other, but not to the skull, utilizing the X-rays and photographs at the Archives. The three to your right are

the fragments removed from the limousine of the President and brought to the autopsy doctors during the course of the autopsy; and the fourth fragment is a separate fragment found a few days later in Dealey Plaza and referred to as the Harper fragment.

These four fragments did emanate from the large defect in the side of the President's head.

The position of the President's head in both of these diagrams was derived from Zapruder frame 312, which, as I already mentioned, shows the position of the President just before the explosion of the head.

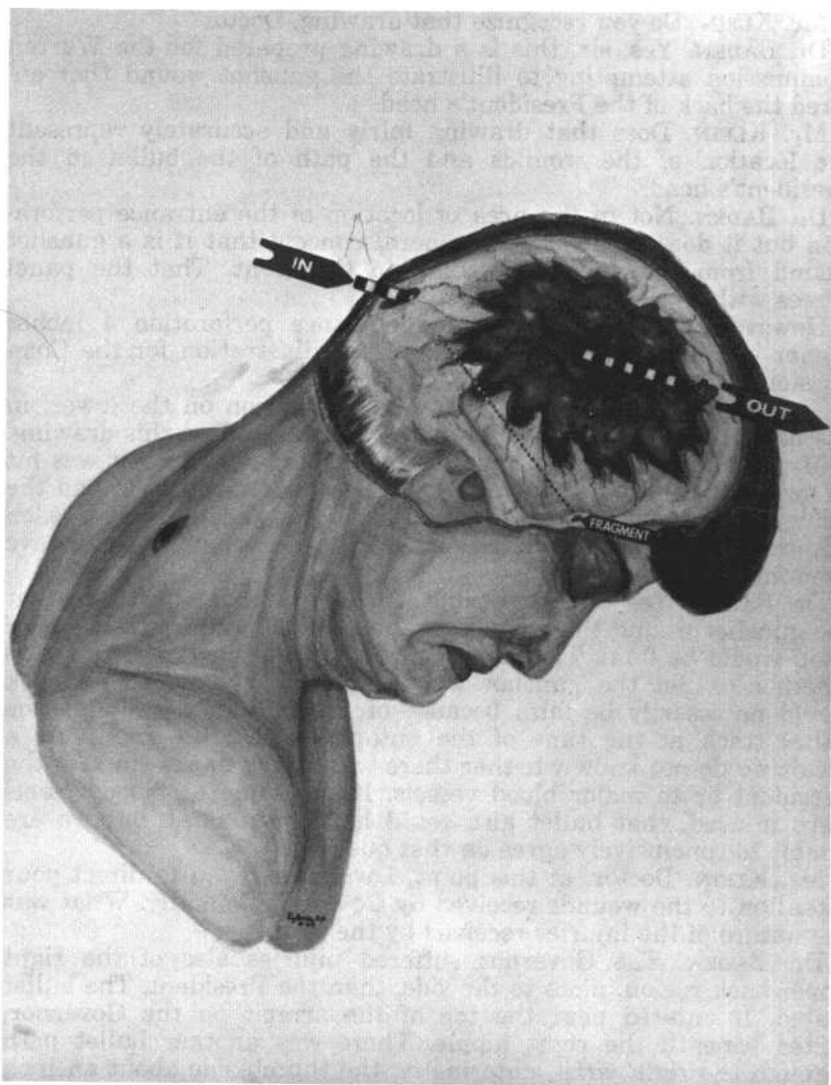Mr. KLEIN. Did the panel conclude that the direction of the bullet was downward?

Dr. BADEN. Yes, in this instance the panel was able to arrive at a conclusion of the directionality from whence the bullet originated because of other evidence made available to the panel, notably, the Zapruder film showing the position of the head of the President at the moment of impact with the bullet.

Mr. KLEIN. Mr. Chairman, at this time, I would ask that the drawing marked JFK F-68 be received as a committee exhibit.

Chairman STOKES. Without objection, it may be received at this point.

[The above referred to JFK exhibit F-68 follows:]



JFK Exhibit F-68

Mr. KLEIN. Do you recognize that drawing, Doctor?

Dr. BADEN. Yes, sir, this is a drawing prepared for the Warren Commission attempting to illustrate the gunshot wound that entered the back of the President's head.

Mr. KLEIN. Does that drawing fairly and accurately represent the location of the wounds and the path of the bullet in the President's head?

Dr. BADEN. Not in the area of location of the entrance perforation but it does illustrate the general concept that it is a gunshot wound from the back proceeding to the front. That the panel agrees with.

However, the panel places the entrance perforation 4 inches higher in the back of the head than the illustration for the Commission shows.

The panel also places the entrance perforation on the lower, in the back area, a few inches lower than illustrated on this drawing.

Mr. KLEIN. Doctor, you have testified that the President was hit by two bullets, one of which entered his upper right back, and the other entered high on the back of his head. Did the panel reach any conclusions as to whether each of these wounds would have been fatal in and of itself?

Dr. BADEN. Yes, the panel did conclude, without question, that the gunshot wound that struck the head of the President in and of itself would be fatal. The panel could not unanimously agree as to whether or not the gunshot wound through the back and neck would necessarily be fatal because of the failure to examine the bullet track at the time of the autopsy—dissect the track. As a result we do not know whether there was injury to the spine of the President or to major blood vessels. If the spine or blood vessels were injured, that bullet also could have been fatal, but we are unable to conclusively agree on that question.

Mr. KLEIN. Doctor, at this point, I would ask you to direct your attention to the wounds received by Governor Connally. What was the nature of the injuries received by the Governor?

Dr. BADEN. The Governor suffered injuries also of the right upper back region, more to the side, than the President. The bullet exited. It entered near the top of the armpit on the Governor, exited beneath the right nipple. There was another bullet path through the right wrist, entering on the thumb side about an inch above the wrist, exiting on the palm aspect of the wrist, and there was another bullet perforation in the left inner thigh of the Governor.

Mr. KLEIN. Mr. Chairman, I would ask that these reports marked JFK F-70 and F-71 be received as committee exhibits and shown to the witness.

Chairman STOKES. Without objection, they may be received.
[The above referred to JFK exhibits F-70 and F-71 follow.]

JFK EXHIBIT F-70

Tuesday, April 21, 1964

TESTIMONY OF DR. ROBERT ROEDER SHAW, DR. CHARLES FRANCIS GREGORY, GOV. JOHN BOWDEN CONNALLY, JR., AND MRS. JOHN BOWDEN CONNALLY, JR.

The President's Commission met at 1:30 p.m., on April 21, 1964, at 200 Maryland Avenue NE., Washington, D.C.

Present were Chief Justice Earl Warren, Chairman; Senator Richard B. Russell, Senator John Sherman Cooper, Representative Hale Boggs, John J. McCloy, and Allen W. Dulles, members.

Also present were J. Lee Rankin, general counsel; Francis W. H. Adams, assistant counsel; Joseph A. Ball, assistant counsel; David W. Belin, assistant counsel; Norman Redlich, assistant counsel; Arlen Specter, assistant counsel; Charles Murray and Charles Rhyne, observers; and Waggoner Carr, attorney general of Texas.

TESTIMONY OF DR. ROBERT ROEDER SHAW

Senator COOPER. The Commission will come to order.

Dr. Shaw, you understand that the purpose of this inquiry is taken under the order of the President appointing the Commission on the assassination of President Kennedy to investigate all the facts relating to his assassination.

Dr. SHAW. I do.

Senator COOPER. And report to the public.

Do you solemnly swear the testimony you are about to give before this Commission will be the truth, the whole truth, and nothing but the truth, so help you God?

Dr. SHAW. I do.

Senator COOPER. Do you desire an attorney to be with you?

Dr. SHAW. No.

Mr. SPECTER. Will you state your full name for the record, please?

Dr. SHAW. Robert Roeder Shaw.

Mr. SPECTER. What is your profession, please?

Dr. SHAW. Physician and surgeon.

Mr. SPECTER. Will you outline briefly your educational background?

Dr. SHAW. I received my B.A. degree from the University of Michigan in 1927, and my M.D. degree from the same institution in 1933.

Following that I served 2 years at the Roosevelt Hospital in New York City from July 1934, to July 1936, in training in general surgery. I had then 2 years of training in thoracic surgery at the University Hospital, Ann Arbor, Mich., from July 1936 to July 1938.

On August 1, 1938, I entered private practice limiting my practice to thoracic surgery in Dallas, Tex.

Mr. DULLES. What kind of surgery?

Dr. SHAW. Thoracic surgery or surgery of the chest.

I have practiced there continuously except for a period from June 1942, until December 1945, when I was a member of the Medical Corps of the Army of the United States serving principally in the European theater of operations.

I was away again from December 1961, until June of 1963, when I was head of the MEDICO team and performed surgery at Avicenna Hospital in Kabul, Pakistan.

Mr. DULLES. Will you tell us a little bit about MEDICO. Is that the ship?

Dr. SHAW. No; that is HOPE. MEDICO was formed by the late Dr. Tom Dooley.

Mr. DULLES. Yes; I know him very well. He was the man in Laos.

Dr. SHAW. Yes, sir; this was one of their projects.

Mr. DULLES. I see.

Dr. SHAW. I returned to—

Mr. DULLES. An interesting project.

Dr. SHAW. I returned to Dallas and on September 1, 1963, started working full time with the University of Texas Southwestern Medical School as professor of thoracic surgery and chairman of the division of thoracic surgery.

In this position I also am chief of thoracic surgery at Parkland Memorial Hospital in Dallas which is the chief hospital from the standpoint of the medical facilities of the school.

Mr. SPECTER. Are you licensed to practice medicine in the State of Texas?

Dr. SHAW. I am.

Mr. SPECTER. Are you certified?

Dr. SHAW. By the board of thoracic surgery you mean?

Mr. SPECTER. Yes; by the board of thoracic surgery.

Dr. SHAW. Yes; as of 1948.

Mr. SPECTER. What experience, if any, have you had, Dr. Shaw, with bullet wounds?

Dr. SHAW. I have had civilian experience, both in the work at Parkland Hospital, where we see a great amount of trauma, and much of this involves bullet wounds from homicidal attempts and accidents.

The chief experience I had, however, was during the Second World War when I was serving as chief of the thoracic surgery center in Paris, France. And during this particular experience we admitted over 900 patients with chest wounds of various sort, many of them, of course, being shell fragments rather than bullet wounds.

Mr. SPECTER. What is your best estimate as to the total number of bullet wounds you have had experience with?

Dr. SHAW. It would be approximately 1,000, considering the large number of admissions we had in Paris.

Mr. SPECTER. What were your duties in a general way on November 22, 1963.

Dr. SHAW. On that particular date I had been at a conference at Woodlawn Hospital, which is our hospital for medical chest diseases connected with the medical school system. I had just gone to the Children's Hospital to see a small patient that I had done a bronchoscopy on a few days before and was returning to Parkland Hospital, and the medical school.

Woodlawn and the Children's Hospital are approximately a mile away from Parkland Hospital.

Mr. SPECTER. Were you called upon to render any aid to President Kennedy on November 22?

Dr. SHAW. No.

Mr. SPECTER. Were you called upon to render medical aid to Gov. John B. Connally on that day?

Dr. SHAW. Yes.

Mr. SPECTER. Will you describe briefly the circumstances surrounding your being called into the case.

Dr. SHAW. As I was driving toward the medical school I came to an intersection of Harry Hines Boulevard and Industrial Boulevard.

There is also a railroad crossing at this particular point. I saw an open limousine pass this point at high speed with a police escort. We were held up in traffic because of this escort. Finally, when we were allowed to proceed, I went on to the medical school expecting to eat lunch. I had the radio on because it was the day that I knew the President was in Dallas and would be eating lunch at the Trade Mart which was not far away, and over the radio I heard the report that the President had been shot at while riding in the motorcade. I went on to the medical school and as I entered the medical school a student came in and joined three other students, and said the President has just been brought into the emergency room at Parkland, dead on arrival.

The students said, "You are kidding, aren't you?" and he said, "No, I am not. I saw him, and Governor Connally has been shot through the chest."

Hearing that I turned and walked over to the emergency room, which is approximately 150 yards from the medical school, and entered the emergency room.

Mr. SPECTER. At approximately what time did you arrive at the emergency room where Governor Connally was situated?

Dr. SHAW. As near as I could tell it was about 12:45.

Mr. SPECTER. Who was with Governor Connally, if anyone, at that time, Dr. Shaw?

Dr. SHAW. I immediately recognized two of the men who worked with me in thoracic surgery, Dr. James Duke and Dr. James Boland, Dr. Giesecke, who is an anesthesiologist, was also there along with a Dr. David Mebane who is an instructor in general surgery.

Mr. SPECTER. What was Governor Connally's condition at that time, based on your observations?

Dr. SHAW. The Governor was complaining bitterly of difficulty in breathing, and of pain in his right chest. Prior to my arriving there, the men had very properly placed a tight occlusive dressing over what on later examination proved to be a large sucking wound in the front of his right chest, and they had inserted a rubber tube between the second and third ribs in the front of the right chest, carrying this tube to what we call a water seal bottle.

Mr. SPECTER. What was the purpose?

Dr. SHAW. Yes; this is done to reexpand the right lung which had collapsed due to the opening through the chest wall.

Mr. SPECTER. What wounds, if any, did you observe on the Governor at that time?

Dr. SHAW. I observed no wounds on the Governor at this time. It wasn't until he was taken to the operating room that I properly examined him from the standpoint of the wound.

Mr. SPECTER. How long after your initial viewing of him was he taken to the operating room?

Dr. SHAW. Within about 5 minutes. I stepped outside to talk to Mrs. Connally because I had been given information by Dr. Duke that blood had been drawn from the Governor, sent to the laboratory for cross-matching for blood that we knew would be necessary, that the operating room had already been alerted, and that they were ready and they were merely awaiting my arrival.

Mr. SPECTER. How was Governor Connally transported from the emergency room to the operating room?

Dr. SHAW. On a stretcher.

Mr. SPECTER. And was he transported up an elevator as well?

Dr. SHAW. Yes. It is two floors above the emergency rooms.

Mr. SPECTER. Will you describe what happened next in connection with Governor Connally's—

Mr. DULLES. Could I ask a question, putting in this tube is prior to making an incision?

Dr. SHAW. Yes; a stab wound.

Mr. DULLES. Just a stab wound?

Dr. SHAW. Yes.

Mr. SPECTER. What treatment next followed for Governor Connally, Doctor?

Dr. SHAW. He was taken to the operating room and there Dr. Giesecke started the anesthesia. This entails giving an intravenous injection of sodium pentothal and then after the Governor was asleep a gas was used, that will be on the anesthetic record there.

Mr. SPECTER. Do you know at approximately what time this procedure was started?

Dr. SHAW. I will have to refresh my memory again from the record. We had at the time I testified before, we had the—

Mr. SPECTER. Permit me to make available to you a copy of the Parkland Memorial Hospital operative record and let me ask you, first of all, if you can identify these two pages on an exhibit heretofore marked as Commission Exhibit 392 as to whether or not this constitutes your report?

Dr. SHAW. Yes; this is a transcription of my dictated report of the operation.

Mr. SPECTER. Are the facts set forth therein true and correct?

Dr. SHAW. Yes. On this it states that the operation itself was begun at 1300 hours or 1 o'clock, 1 p.m., and that the actual surgery started at 1335 or 1:35 p.m. The operation was concluded by me at 3—1520 which would be 3:20 p.m.

Mr. SPECTER. You have described, in a general way, the chest wound. What other wounds, if any, was Governor Connally suffering from at the time you saw him?

Dr. SHAW. I will describe then the wound of the wrist which was obvious. He had a wound of the lower right forearm that I did not accurately examine because I had already talked to Dr. Gregory while I was scrubbing for the operation, told him that this wound would need his attention as soon as we were able to get the chest in a satisfactory condition. There was also, I was told, I didn't see the wound, on the thigh, I was told that there was a small wound on the thigh which I saw later.

Mr. SPECTER. When did you first have an opportunity then to examine Governor Connally's wound on the posterior aspect of his chest?

Dr. SHAW. After the Governor had been anesthetized. As soon as he was asleep so we could manipulate him—before that time it was necessary for an endotracheal tube to be in place so his respirations could be controlled before we felt we could roll him over and accurately examine the wound entrance.

We knew this was the wound exit.

Mr. SPECTER. This [indicating an area below the right nipple on the body]?

Dr. SHAW. Yes.

Mr. DULLES. How did you know it was a wound exit.

Dr. SHAW. By the fact of its size, the ragged edges of the wound. This wound was covered by a dressing which could not be removed until the Governor was anesthetized.

Mr. SPECTER. Indicating this wound, the wound on the Governor's chest?

Dr. SHAW. Yes; the front part.

Mr. SPECTER. Will you describe in as much detail as you can the wound on the posterior side of the Governor's chest?

Dr. SHAW. This was a small wound approximately a centimeter and a half in its greatest diameter. It was roughly elliptical. It was just medial to the axillary fold or

the crease of the armpit, but we could tell that this wound, the depth of the wound, had not penetrated the shoulder blade.

Mr. SPECTER. What were the characteristics, if any, which indicated to you that it was a wound of entrance then?

Dr. SHAW. Its small size, and the rather clean cut edges of the wound as compared to the usual more ragged wound of exit.

Mr. SPECTER. Now, I hand you a diagram which is a body diagram on Commission Exhibit No. 679, and ask you if, on the back portion of the figure, that accurately depicts the point of entry into Governor Connally's back?

Dr. SHAW. Yes. The depiction of the point of entry, I feel is quite accurate.

Mr. SPECTER. Now, with respect to the front side of the body, is the point of exit accurately shown on the diagram?

Dr. SHAW. The point is—

Mr. SPECTER. We have heretofore, may the record show the deposition covered much the same ground with Dr. Shaw, but the diagrams used now are new diagrams which will have to be remarked in accordance with your recollection.

Dr. SHAW. Yes. Because I would have to place—they are showing here the angle.

Mr. DULLES. Is this all on the record?

Mr. SPECTER. It should be.

Dr. SHAW. We are showing on this angle, the cartilage angle which it makes at the end of the sternum.

Mr. SPECTER. That is an inverted V which appears in front of the body?

Dr. SHAW. Now the wound was above that. They have shown it below that point so the wound would have to be placed here as far as the point is concerned.

Mr. SPECTER. Would you draw on that diagram a more accurate depiction of where the wound of exit occurred?

Dr. SHAW. Do you want me to initial this?

Mr. SPECTER. Yes; if you please, Dr. Shaw.

I hand you another body diagram marked Commission Exhibit 680 and I will ask you if that accurately depicts the angle of decline as the bullet passed through Governor Connally?

Dr. SHAW. I think the declination of this line is a little too sharply downward. I would place it about 5° off that line.

Mr. SPECTER. Will you redraw the line then, Dr. Shaw, and initial it, indicating the more accurate angle?

Dr. SHAW. The reason I state this is that as they have shown this, it would place the wound of exit a little too far below the nipple. Also it would, since the bullet followed the line of declination of the fifth rib, it would make the ribs placed in a too slanting position.

Mr. SPECTER. What operative procedures did you employ in caring for the wound of the chest, Dr. Shaw.

Dr. SHAW. The first measure was to excise the edges of the wound of exit in an elliptical fashion, and then this incision was carried in a curved incision along the lateral portion of the right chest up toward the right axilla in order to place the skin incision lower than the actual path of the bullet through the chest wall.

After this incision had been carried down to the level of the muscles attached to the rib cage, all of the damaged muscle which was chiefly the serratus anterior muscle which digitates along the fifth rib at this position, was cleaned away, cut away with sharp dissection.

As soon as—of course, this incision had been made, the opening through the parietal pleura, which is the lining of the inside of the chest was very obvious. It was necessary to trim away several small fragments of the rib which were still hanging to tags of periosteum, the lining of the rib, and the ragged ends of the rib were smoothed off with a rongeur.

Mr. SPECTER. What damage had been inflicted upon a rib, if any, Dr. Shaw?

Dr. SHAW. About 10 centimeters of the fifth rib starting at the, about the mid-axillary line and going to the anterior axillary line, as we describe it, or that would be the midline at the armpit going to the anterior lateral portion of the chest, had been stripped away by the missile.

Mr. SPECTER. What is the texture of the rib at the point where the missile struck?

Dr. SHAW. The texture of the rib here is not of great density. The cortex of the rib in the lateral portions of our ribs, is thin with the so-called cancellus portion of the rib being very spongy, offering very little resistance to pressure or to fracturing.

Mr. SPECTER. What effect, if any, would the striking of that rib have had to the trajectory of the bullet?

Dr. SHAW. It could have had a slight, caused a slight deflection of the rib, but probably not a great deflection of the rib, because of the angle at which it struck and also because of the texture of the rib at this time.

Mr. SPECTER. You say deflection of the rib or deflection of the bullet?

Dr. SHAW. Deflection of the bullet, I am sorry.

Mr. SPECTER. Was any metallic substance from the bullet left in the thoracic cage as a result of the passage of the bullet through the Governor's body?

Dr. SHAW. No. We saw no evidence of any metallic material in the X-ray that we had of the chest, and we found none during the operation.

Mr. SPECTER. Have you brought the X-rays with you. Dr. Shaw, from Parkland Hospital?

Dr. SHAW. Yes; we have them here.

Mr. SPECTER. May the record show we have available a viewer for the X-rays.

Dr. Shaw, would you, by use of the viewer, exhibit the X-rays of the Governor's chest to show more graphically that which you have heretofore described?

Dr. SHAW. This is the first X-ray that was taken, which was taken in the operating room with the Governor on the operating table, and at this time anesthetized. The safety pin that you see here is used, was used, to secure the tube which had been put between the second and third rib in expanding the Governor's lung.

We can dimly see also the latex rubber tube up in the chest coming to the apex of the chest.

The variations that we see from normal here are the fact that first, there is a great amount of swelling in the chest wall which we know was due to bleeding and bruising of the tissues of the chest wall, and we also see that there is air in the tissues of the chest wall here and here. It is rather obvious.

Mr. SPECTER. When you say here and here, you are referring to the outer portions, showing on the X-ray moving up toward the shoulder area?

Dr. SHAW. Yes; going from the lower chest up to the region near the angle of the shoulder blade.

The boney framework of the chest, it is obvious that the fifth rib, we count ribs from above downward, this is the first rib, second rib, third rib, fourth rib, fifth rib, that a portion of this rib has been shattered, and we can see a few fragments that have been left behind.

Also the rib has because of being broken and losing some of its substance, has taken a rather inward position in relation to the fourth and the sixth ribs on either side.

Mr. SPECTER. What effect was there, if any, on the upper portion of that rib?

Dr. SHAW. This was not noticed at the time of this examination, Mr. Specter. However, in subsequent examinations we can tell that there was a fracture across the rib at this point due to the rib being struck and bent.

Mr. SPECTER. When you say this point, will you describe where that point exists on the X-ray?

Dr. SHAW. This is a point approximately 4 centimeters from its connection with the transverse process of the spine.

Mr. SPECTER. And is the fracture, which is located there, caused by a striking there or by the striking at the end of the rib?

Dr. SHAW. It is caused by the striking at the end of the rib.

Mr. SPECTER. Fine. What else then is discernible from the viewing of the X-ray, Dr. Shaw?

Dr. SHAW. There is a great amount of, we would say, obscuration of the lower part of the right lung field which we know from subsequent examination was due to blood in the pleural cavity and also due to a hematoma in the lower part of the right lower lobe and also a severe laceration of the middle lobe with it having lost its ability to ventilate at that time. So, we have both an airless lung, and blood in the lung to account for these shadows.

Mr. SPECTER. Is there anything else visible from the X-ray which is helpful in our understanding of the Governor's condition?

Dr. SHAW. No; I don't think so.

Mr. SPECTER. Would it be useful—As to that X-ray, Dr. Shaw, will you tell us what identifying data, if any, it has in the records of Parkland Hospital, for the record?

Dr. SHAW. On this X-ray it has in pencil John G. Connally.

Mr. SPECTER. Is that G or C?

Dr. SHAW. They have a "G" November 22, 1963, and it has a number 218-922.

Mr. SPECTER. Were those X-rays taken under your supervision?

Dr. SHAW. Yes, by a technician.

Mr. SPECTER. And that is, in fact, the X-ray then which was taken of Governor Connally at the time these procedures were being performed?

Dr. SHAW. It is.

Mr. SPECTER. Dr. Shaw, would any of the other X-rays be helpful in our understanding of the Governor's condition?

Dr. SHAW. I believe the only—perhaps showing one additional X-ray would show the fracture previously described which was not easily discernible on the first film. This is quite often true but not important to the—here is the fracture that can be easily seen.

Mr. SPECTER. You are now referring to a separate and second X-ray.

Dr. SHAW. Yes.

Mr. SPECTER. Will you start out by telling us on what date this X-ray was performed.

Dr. SHAW. This X-ray was made on the 29th of November 1963, 7 days following the incident.

Mr. SPECTER. What does it show of significance?

Dr. SHAW. It shows that there has been considerable clearing in the lower portion of the lung, and also that there is a fracture of the fifth rib as previously described approximately 4 centimeters from the transverse process posteriorly.

Mr. SPECTER. Is there anything else depicted by that X-ray of material assistance in evaluating the Governor's wound?

Dr. SHAW. No.

Mr. McCLOY. Were there any photographs taken as distinguished from X-rays of the body?

Dr. SHAW. There were no photographs.

Mr. SPECTER. Dr. Shaw, we shall then, subject to the approval of the Commission, for the record, have the X-rays reproduced at Parkland Memorial Hospital, and, if possible, also have a photograph of the X-ray made for the permanent records of the Commission to show the actual X-ray, which Dr. Shaw has described during his testimony here this afternoon.

Senator COOPER. It is directed that it be made a part of the record of these hearings.

Mr. SPECTER. Dr. Shaw, what additional operative procedures did you perform on Governor Connally's chest?

Dr. SHAW. I will continue with my description of the operative procedure. The opening that had been made through the rib after the removal of the fragments was adequate for further exploration of the pleural cavity. A self-retaining retractor was put into place to maintain exposure. Inside the pleural cavity there were approximately 200 cc. of clotted blood.

It was found that the middle lobe had been lacerated with the laceration dividing the lobe into roughly two equal parts. The laceration ran from the lower tip of the middle lobe up into its root or hilum.

However, the lobe was not otherwise damaged, so that it could be repaired using a running suture of triple zero chromic catgut.

The anterior basal segments of the right lower lobe had a large hematoma, and blood was oozing out of one small laceration that was a little less than a centimeter in length, where a rib fragment had undoubtedly been driven into the lobe. To control hemorrhage a single suture of triple zero chromic gut was placed in this laceration. There were several small matchstick size fragments of rib within the pleural cavity. Examination, however, of the pericardium of the diaphragm and the upper lobe revealed no injury to these parts of the chest.

A drain was placed in the eighth space in the posterior axillary line similar to the drain which had been placed in the second interspace in the front of the chest.

The drain in the front of the chest was thought to be a little too long so about 3 centimeters of it were cut away.

Attention was then turned on the laceration of the latissimus dorsi muscle where the missile had passed through it. Several sutures of chromic gut were used to repair this muscle.

The inclusion was then closed with interrupted No. zero chromic gut in the muscles of the chest wall—first, I am sorry, in the intercostal muscle, and muscles of the chest wall, and the same suture material was used to close the serratus anterior muscle in the subcutaneous tissue, and interrupted vertical sutures of black silk were used to close the skin.

Attention was then turned to the wound of entrance which, as previously described, was about a centimeter and a half in its greatest diameter, roughly elliptical in shape. The skin edges of this wound were incised—excised, I beg your pardon—I have to go back just a little bit.

Prior to examination of this wound, a stab wound was made at the angle of the scapula to place a drain in the subscapular space. In the examination of the wound of entrance, the examining finger could determine that this drain was immediately under the wound of entrance, so that it was adequately draining the space.

Two sutures were placed in the fascia of the muscle, and the skin was closed with interrupted vertical matching sutures of black silk.

That concluded the operation. Both tubes were connected to a water seal bottle, and the dressing was applied.

Mr. SPECTER. Who was in charge then of the subsequent care on the Governor's wrist?

Dr. SHAW. Dr. Charles Gregory who had been previously alerted and then came in to take care of the wrist.

Mr. SPECTER. Now, with respect to the wound on the wrist, did you have any opportunity to examine it by way of determining points of entry and exit?

Dr. SHAW. My examination of the wrist was a very cursory one. I could tell that there was a compound comminuted fracture because there was motion present, and there was a ragged wound just over the radius above the wrist joint. But that was the extent of my examination of the wrist.

Mr. SPECTER. Dr. Shaw, did I take your deposition at Parkland Memorial Hospital on March 23 of 1964?

Dr. SHAW. Yes; you did.

Mr. SPECTER. Has that deposition been made available to you?

Dr. SHAW. Yes.

Mr. SPECTER. To you here this afternoon?

Dr. SHAW. Yes.

Mr. SPECTER. Have you subsequent to the giving of that deposition on March 23, 1964, had an opportunity to examine Governor Connally's clothing which we have available in the Commission room here today?

Dr. SHAW. Yes.

Mr. SPECTER. Now, based on all facts now within your knowledge, is there any modification which you would care to make in terms of the views which you expressed about entrance and exit wounds, back on March 23, based on the information which was available to you at that time?

Dr. SHAW. From an examination of the clothing, it is very obvious that the wound of entrance was through the coat sleeve.

Mr. SPECTER. While you are testifying in that manner, perhaps it would be helpful if we would make available to you the actual jacket, if it pleases the Commission.

We shall reserve Exhibits Nos. 681 for the X-ray of November 22; 682 for the X-ray of November 29; and we shall now mark a photograph of the coat for our permanent records as "Commission Exhibit No. 683".

Dr. Shaw, I hand you at this time what purports to be the coat worn by Governor Connally, which we introduce subject to later proof when Governor Connally appears later this afternoon; and, for the record, I ask you first of all if this photograph, designated as Commission Exhibit No. 683, is a picture of this suit coat?

Dr. SHAW. It is.

Mr. SPECTER. I had interrupted you when you started to refer to the hole in the sleeve of the coat. Will you proceed with what you were testifying about there?

Dr. SHAW. The hole in the sleeve of the coat is within half a centimeter of the very edge of the sleeve, and lies—

Mr. DULLES. This is the right sleeve, is it not?

Dr. SHAW. I am sorry, yes. Thank you. Of the right sleeve, and places it, if the coat sleeve was in the same position, assuming it is in the same position that my coat sleeve is in, places it directly over the lateral portion of the wrist, really not directly on the volar or the dorsum of the surface of the wrist, but on the lateral position or the upper position, as the wrist is held in a neutral position.

Mr. SPECTER. With the additional information provided by the coat, would that enable you to give an opinion as to which was the wound of entrance and which the wound of exit on the Governor's wrist?

Dr. SHAW. There is only tear in the Governor's garment, as far as the appearance of the tear is concerned, I don't think I could render an opinion as to whether this is a wound of entrance or exit.

Mr. SPECTER. Then, do you have sufficient information at your disposal in total, based on your observations and what you know now to give any meaningful opinion as to which was the wound of entrance and which the wound of exit on the Governor's wrist?

Dr. SHAW. I would prefer to have Dr. Gregory testify about that, because he has examined it more carefully than I have.

Mr. SPECTER. Fine.

Mr. DULLES. Could you tell at all how the arm was held from that mark or that hole in the sleeve?

Dr. SHAW. Mr. Dulles, I thought I knew just how the Governor was wounded until I saw the pictures today, and it becomes a little bit harder to explain.

I felt that the wound had been caused by the same bullet than came out through the chest with the Governor's arm held in approximately this position.

Mr. SPECTER. Indicating the right hand held close to the body?

Dr. SHAW. Yes, and this is still a possibility. But I don't feel that it is the only possibility.

Senator COOPER. Why do you say you don't think it is the only possibility? What causes you now to say that it is the location—

Dr. SHAW. This is again the testimony that I believe Dr. Gregory will be giving, too. It is a matter of whether the wrist wound could be caused by the same bullet, and we felt that it could but we had not seen the bullets until today, and we still do not know which bullet actually inflicted the wound on Governor Connally.

Mr. DULLES. Or whether it was one or two wounds?

Dr. SHAW. Yes.

Mr. DULLES. Or two bullets?

Dr. SHAW. Yes; or three.

Mr. DULLES. Why do you say three?

Dr. SHAW. He has three separate wounds. He has a wound in the chest, a wound of the wrist, a wound of the thigh.

Mr. DULLES. Oh, yes; we haven't come to the wound of the thigh, yet, have we?

Mr. MCCLOY. You have no firm opinion that all these three wounds were caused by one bullet?

Dr. SHAW. I have no firm opinion.

Mr. MCCLOY. That is right.

Dr. SHAW. Asking me this now if it was true. If you had asked me a month ago I would have.

Mr. DULLES. Could they have been caused by one bullet, in your opinion?

Dr. SHAW. They could.

Mr. MCCLOY. I gather that what the witness is saying is that it is possible that they might have been caused by one bullet. But that he has no firm opinion now that they were.

Mr. DULLES. As I understand it too. Is our understanding correct?

Dr. SHAW. That is correct.

Senator COOPER. When you say all three are your referring to the wounds you have just described to the chest, the wound in the wrist, and also the wound in the thigh?

Dr. SHAW. Yes.

Senator COOPER. It was possible?

Dr. SHAW. Our original assumption, Senator Cooper, was that the Governor was approximately in this attitude at the time he was—

Senator COOPER. What attitude is that now?

Dr. SHAW. This is an attitude sitting in a jump seat as we know he was, upright, with his right forearm held across the lower portion of the chest. In this position, the trajectory of the bullet could have caused the wound of entrance, the wound of exit, struck his wrist and proceeded on into the left thigh. But although this is a possibility, I can't give a firm opinion that this is the actual way in which it occurred.

Mr. SPECTER. If it pleases the Commission, we propose to go through that in this testimony; and we have already started to mark other exhibits in sequence on the clothing. So that it will be more systematic, we plan to proceed with the identification of clothing and then go on to the composite diagram which explains the first hypothesis of Dr. Shaw and the other doctors of Parkland. And then proceed from that, as I intend to do with an examination of the bullet, which will explore the thinking of the doctor on that subject.

Dr. Shaw, for our record, I will hand you Commission Exhibit No. 684 and ask you if that is a picture of the reverse side of the coat, which we will later prove to have been worn by Governor Connally, the coat which is before you?

Dr. SHAW. It is.

Mr. SPECTER. What, if anything, appears on the back of that coat and also on the picture in line with the wound which you have described on the Governor's posterior chest?

Dr. SHAW. The picture—the coat and the picture of the coat, show a rent in the back of the coat approximately 2 centimeters medial to the point where the sleeve has been joined to the main portion of the garment.

The lighter-colored material of the lining of the coat can be seen through this rent of the coat.

Mr. SPECTER. Dr. Shaw, I show you a shirt, subject to later proof that it was the shirt worn by Governor Connally, together with a photograph marked "Commission Exhibit No. 685," and ask you if that is a picture of that shirt, the back side of the shirt?

Dr. SHAW. Yes; it is a picture of the back side of the shirt. However, in this particular picture I am not able to make out the hole in the shirt very well.

Now I see it, I believe; yes.

Mr. SPECTER. Will you describe the hole as you see it to exist in the shirt? Aside from what you see on the picture, what hole do you observe on the back of the shirt itself?

Dr. SHAW. On the back of the shirt itself there is a hole, a punched out area of the shirt which is a little more than a centimeter in its greater diameter. The whole shirt is soiled by brown stains which could have been due to blood.

Mr. SPECTER. How does the hole in the back of the shirt correspond with the wound on the Governor's back?

Dr. SHAW. It does correspond exactly.

Mr. SPECTER. Now turning the same shirt over to the front side, I ask you if the photograph, marked "Commission Exhibit No. 386," is a picture of the front side of this shirt?

Dr. SHAW. It is.

Mr. SPECTER. What does the picture of the shirt show with respect to a hole, if any, on the right side of the front of the shirt?

Dr. SHAW. The picture and the shirt show on the right side a much larger rent in the garment with the rent being approximately 4 centimeters in its largest diameter.

Mr. SPECTER. What wound, if any, did the Governor sustain on his thigh, Dr. Shaw?

Mr. DULLES. Just one moment, are you leaving this?

Mr. SPECTER. Yes.

Mr. DULLES. I wonder whether or not it would not be desirable for the doctor to put this photograph where these holes are, because they are not at all clear for the future if we want to study those photographs.

Dr. SHAW. This one is not so hard.

Mr. DULLES. That one appears but the other one doesn't appear and I think it would be very helpful.

Dr. SHAW. How would you like to have me outline this?

Mr. SPECTER. Draw a red circle of what you conceive to be the hole there, Doctor.

Mr. DULLES. The actual hole is not nearly as big as your circle, it is the darkened area inside that circle, is it not?

Dr. SHAW. Yes; the darkened area is enclosed by the circle.

Mr. SPECTER. Are you able to note on the photograph of the back of the shirt, 685?

Will you draw a red circle around the area of the hole on the photograph then, Dr. Shaw?

Mr. DULLES. Would you just initial those two circles, if you can.

Mr. SPECTER. Dr. Shaw, what wounds, if any, did the Governor sustain on his left thigh?

Dr. SHAW. He sustained a small puncture-type wound on the medial aspect of the left thigh.

Mr. SPECTER. Did you have an opportunity to examine that closely?

Dr. SHAW. No.

Mr. SPECTER. Did you have an opportunity to examine it sufficiently to ascertain its location on the left thigh?

Dr. SHAW. No; I didn't examine it that closely, except for its general location.

Mr. SPECTER. Where was it with respect to a general location then on the Governor's thigh?

Dr. SHAW. It is on the medial anterior aspect of thigh.

Mr. DULLES. Nontechnically, what does it mean?

Dr. SHAW. Well, above, slightly above, between, in other words, the medial aspect would be the aspect toward the middle of the body, but as far as being how many centimeters or inches it is from the knee and the groin, I am not absolutely sure.

Mr. SPECTER. I now show you a pair of trousers which we shall later identify as being those worn by the Governor. I will, first of all, ask you if a photograph bearing Commission Exhibit No. 687 is a picture of those trousers?

Dr. SHAW. It is.

Mr. SPECTER. And what hole, if any did you observe on the trousers and on the picture of the trousers?

Dr. SHAW. There is a hole in the garment that has been made by some instrument which has carried away a part of the Governor's garment. In other words, it is not a tear but is a punched out hole, and this is approximately 4 centimeters on the inner aspect from the crease of the trousers.

Mr. DULLES. Can you tell where the knee is there and how far above the knee approximately?

Dr. SHAW. I can't tell exactly.

Mr. DULLES. I guess you can't tell.

Dr. SHAW. From the crotch I would say it would be slightly, it is a little hard to tell, slightly more toward the knee than the groin.

Mr. SPECTER. Does that hole in the left leg of the trousers match up to the wound on the left thigh of the Governor?

Dr. SHAW. To the best of my recollection it does.

Mr. DULLES. Are there any other perforations in these trousers at all, any other holes?

Dr. SHAW. No.

Mr. DULLES. So that means that whatever made the hole on the front side did not come through and make a hole anywhere else in the trousers?

Dr. SHAW. That is correct. It had to be a penetrating wound and not a perforating wound, it didn't go on through.

Mr. SPECTER. Will you turn those trousers over, Dr. Shaw?

Dr. SHAW. I believe we had already looked at it.

Mr. SPECTER. On the reverse side, and state whether or not this picture bearing Commission Exhibit No. 688 accurately depicts the reverse side of the trousers?

Dr. SHAW. Yes; it does.

Mr. SPECTER. Is there any hole shown either on the picture or on the trousers themselves?

Dr. SHAW. No.

Mr. SPECTER. Dr. Shaw, I now show you a body diagram which is marked "Commission Exhibit No. 689."

Senator COOPER. May I ask a question before you ask that question?

When you first saw Governor Connally in the emergency room was he dressed or undressed?

Dr. SHAW. His trousers were still on. He had his shorts on, I should say, Senator Cooper, but his coat, shirt, and trousers had been removed.

Mr. SPECTER. Were his clothes anywhere in the vicinity where you could have seen them?

Dr. SHAW. No; I never saw them. This is the first time that I saw them.

Mr. SPECTER. That is earlier today when you examined them in this room?

Dr. SHAW. That is correct.

Mr. SPECTER. Looking at Commission Exhibit No. 689, is that a drawing which was prepared, after consultation with you, representing the earlier theory of all of the Governor's wounds having been inflicted by a single missile?

Dr. SHAW. That is correct.

Mr. SPECTER. With reference to that diagram, would you explain the position that you had earlier thought the Governor to have been in when he was wounded here?

Dr. SHAW. We felt that the Governor was in an upright sitting position, and at the time of wounding was turning slightly to the right. This would bring the three wounds, as we know them, the wound in the chest, the wound in the wrist, and the wound in the thigh into a line assuming that the right forearm was held against the lower right chest in front.

The line of inclination of this particular diagram is a little more sharply downward than is probably correct in view of the inclination of the ribs of the chest.

Mr. SPECTER. Will you redraw that line, Dr. Shaw, to conform with what you believe to be—

Dr. SHAW. The fact that the muscle bundles on either side of the fifth rib were not damaged meant that the missile to strip away 10 centimeters of the rib had to follow this rib pretty much along its line of inclination.

Mr. DULLES. I wonder if you could use that red pencil to make it a little clearer for us?

Dr. SHAW. I think these would probably work well on this paper. Perhaps this isn't a tremendous point but it slopes just a little too much.

Mr. SPECTER. You have initiated that to show your incline?

Dr. SHAW. Yes.

Mr. SPECTER. With respect to the wound you described on the thigh, Dr. Shaw, was there any point of exit as to that wound?

Dr. SHAW. No.

Mr. SPECTER. I now show you—

Mr. DULLES. Could I ask one more question there, how deep was the wound of entry, could you tell at all?

Dr. SHAW. Mr. Dulles, I didn't examine the wound of the thigh so I can't testify as to that. Dr. Gregory, I think, was there at the time that the debris was carried out and he may have more knowledge than I have.

Mr. DULLES. We will hear Dr. Gregory later?

Mr. SPECTER. Yes; he is scheduled to testify as soon as Dr. Shaw concludes.

Dr. Shaw, I now show you Commission Exhibit 399 which has heretofore been identified as being a virtually whole bullet weighing 158 grains.

May I say for the record, that in the depositions which have been taken in Parkland Hospital, that we have ascertained, and those depositions are part of the overall record, that is the bullet which came from the stretcher of Governor Connally.

First, Dr. Shaw, have you had a chance to examine that bullet earlier today?

Dr. SHAW. Yes; I examined it this morning.

Mr. SPECTER. Is it possible that the bullet which went through the Governor's chest could have emerged being as fully intact as that bullet is?

Dr. SHAW. Yes; I believe it is possible because of the fact that the bullet struck the fifth rib at a very acute angle and struck a portion of the rib which would not offer a great amount of resistance.

Mr. SPECTER. Does that bullet appear to you to have any of its metal flaked off?

Dr. SHAW. I have been told that the one point on the nose of this bullet that is deformed was cut off for purposes of examination. With that information, I would have to say that this bullet has lost literally none of its substance.

Mr. SPECTER. Now, as to the wound on the thigh, could that bullet have gone into the Governor's thigh without causing any more damage than appears on the face of that bullet?

Dr. SHAW. If it was a spent bullet; yes. As far as the bullet is concerned it could have caused the Governor's thigh wound as a spent missile.

Mr. SPECTER. Why do you say it is a spent missile, would you elaborate on what your thinking is on that issue?

Dr. SHAW. Only from what I have been told by Dr. Shires and Dr. Gregory, that the depth of the wound was only into the subcutaneous tissue, not actually into the muscle of the leg, so it meant that missile had penetrated for a very short period. Am I quoting you correctly, Dr. Gregory?

Mr. SPECTER. May the record show Dr. Gregory is present during this testimony and—

Dr. GREGORY. I will say yes.

Mr. SPECTER. And indicates in the affirmative. Do you have sufficient knowledge of the wound of the wrist to render an opinion as to whether that bullet could have gone through Governor Connally's wrist and emerged being as much intact as it is?

Dr. SHAW. I do not.

Mr. SPECTER. Dr. Shaw, assume if you will certain facts to be true in hypothetical form, that is, that the President was struck in the upper portion of the back or lower portion of the neck with a 6.5-mm. missile passing between the strap muscles of the President's neck, proceeding through a fascia channel striking no bones, not violating the pleural cavity, and emerging through the anterior third of the neck, with the missile having been fired from a weapon having a muzzle velocity of approximately 2,000 feet per second, with the muzzle being approximately 160 to 250 feet from the President's body; that the missile was a copper jacketed bullet. Would it be possible for that bullet to have then proceeded approximately 4 or 5 feet and then would it be possible for it to have struck Governor Connally in the back and have inflicted the wound which you have described on the posterior aspect of his chest, and also on the anterior aspect of his chest?

Dr. SHAW. Yes.

Mr. SPECTER. And what would your reason be for giving an affirmative answer to that question, Dr. Shaw?

Dr. SHAW. Because I would feel that a missile with this velocity and weight striking no more than the soft tissues of the neck would have adequate velocity and mass to inflict the wound that we found on the Governor's chest.

Mr. SPECTER. Now, without respect to whether or not the bullet identified as Commission Exhibit 399 is or is not the one which inflicted the wound on the Governor, is it possible that a missile similar to the one which I have just described in the hypothetical question could have inflicted all of the Governor's wounds in accordance with the theory which you have outlined on Commission Exhibit No. 689?

Dr. SHAW. Assuming that it also had passed through the President's neck you mean?

Mr. SPECTER. No; I had not added that factor in. I will in the next question.

Dr. SHAW. All right. As far as the wounds of the chest are concerned, I feel that this bullet could have inflicted those wounds. But the examination of the wrist both by X-ray and at the time of surgery showed some fragments of metal that make it difficult to believe that the same missile could have caused these two wounds. There seems to be more than three grains of metal missing as far as the—I mean in the wrist.

Mr. SPECTER. Your answer there, though, depends upon the assumption that the bullet which we have identified as Exhibit 399 is the bullet which did the damage to the Governor. Aside from whether or not that is the bullet which inflicted the Governor's wounds.

Dr. SHAW. I see.

Mr. SPECTER. Could a bullet traveling in the path which I have described in the prior hypothetical question, have inflicted all of the wounds on the Governor?

Dr. SHAW. Yes.

Mr. SPECTER. And so far as the velocity and the dimension of the bullet are concerned, is it possible that the same bullet could have gone through the President in the way that I have described and proceed through the Governor causing all of his wounds without regard to whether or not it was bullet 399?

Dr. SHAW. Yes.

Mr. SPECTER. When you started to comment about it not being possible, was that in reference to the existing mass and shape of bullet 399?

Dr. SHAW. I thought you were referring directly to the bullet shown as Exhibit 399.

Mr. SPECTER. What is your opinion as to whether bullet 399 could have inflicted all of the wounds on the Governor, then, without respect at this point to the wound of the President's neck?

Dr. SHAW. I feel that there would be some difficulty in explaining all of the wounds as being inflicted by bullet Exhibit 399 without causing more in the way of loss of substance to the bullet or deformation of the bullet.

(Discussion off the record.)

Mr. SPECTER. Dr. Shaw, have you had an opportunity today here in the Commission building to view the movies which we referred to as the Zapruder movies and the slides taken from these movies?

Dr. SHAW. Yes.

Mr. SPECTER. And what, if any, light did those movies shed on your evaluation and opinions on this matter with respect to the wounds of the Governor?

Dr. SHAW. Well, my main interest was to try to place the time that the Governor was struck by the bullet which inflicted the wound on his chest in reference to the sequence of the three shots, as has been described to us.

(At this point the Chief Justice entered the hearing room.)

This meant trying to carefully examine the position of the Governor's body in the car so that it would fall in line with what we knew the trajectory must be for this bullet coming from the point where it has been indicated it did come from. And in trying to place this actual frame that these frames are numbered when the Governor was hit, my opinion was that it was frame number, let's see, I think it was No. 36.

Mr. SPECTER. 236?

Dr. SHAW. 236, give or take 1 or 2 frames. It was right in 35, 36, 37, perhaps.

Mr. SPECTER. I have heretofore asked you questions about what possibly could have happened in terms of the various combinations of possibilities on missiles striking the Governor in relationship to striking the President as well. Do you have any opinion as to what, in fact, did happen?

Dr. SHAW. Yes. From the pictures, from the conversation with Governor Connally and Mrs. Connally, it seems that the first bullet hit the President in the shoulder and perforated the neck, but this was not the bullet that Governor Connally feels

hit him; and in the sequence of films I think it is hard to say that the first bullet hit both of these men almost simultaneously.

Mr. SPECTER. Is that view based on the information which Governor Connally provided to you?

Dr. SHAW. Largely.

Mr. SPECTER. As opposed to any objectively determinable facts from the bullets, the situs of the wounds of your viewing of the pictures?

Dr. SHAW. I was influenced a great deal by what Governor Connally knew about his movements in the car at this particular time.

Mr. DULLES. You have indicated a certain angle of declination on this chart here which the Chief Justice has.

Dr. SHAW. Yes.

Mr. SPECTER. Do you know enough about the angle of declination of the bullet that hit the President to judge at all whether these two angles of declination are consistent?

Dr. SHAW. We know that the angle of declination was a downward one from back to front so that I think this is consistent with the angle of declination of the wound that the Governor sustained.

Senator COOPER. Are you speaking of the angle of declination in the President's body?

Dr. SHAW. Of the first wound?

Mr. SPECTER. Yes.

Dr. SHAW. First wound

Mr. SPECTER. What you have actually seen from pictures to show the angle of declination?

Dr. SHAW. That is right.

Mr. SPECTER. In the wounds in the President's body?

Dr. SHAW. Yes; that is right. I did not examine the President.

Mr. DULLES. And that angle taking into account say the 4 feet difference between where the President was sitting and where the Governor was sitting, would be consistent with the point of entry of the Governor's body as you have shown it?

Dr. SHAW. The jump seat in the car, as we could see, placed the Governor sitting at a lower level than the President, and I think conceivably these two wounds could have been caused by the same bullet.

Mr. SPECTER. Do you have anything else to add, Dr. Shaw, which you think would be helpful to the Commission in any way?

Dr. SHAW. I don't believe so, Mr. Specter.

Mr. SPECTER. May it please the Commission then I would like to move into evidence Commission Exhibits Nos. 679 and 690, and then reserve Nos. 681 and 682 until we get the photographs of the X-rays and I now move for admission into evidence Commission Exhibits No. 683 through 689.

Senator COOPER. They have all been identified, have they?

Mr. SPECTER. Yes, sir; during the course of Dr. Shaw's testimony.

Senator COOPER. It is ordered then that these exhibits be received in the record. (The documents referred to, previously identified as Commission Exhibits Nos. 679, 680, and 683-689 for identification were received in evidence.)

Mr. McCLOY. Just one or two questions. It is perfectly clear, Doctor, that the wound, the lethal wound on the President did not—the bullet that caused the lethal wound on the President, did not cause any wounds on Governor Connally, in your opinion?

Dr. SHAW. Mr. McCloy, I couldn't say that from my knowledge.

Mr. McCLOY. We are talking about the, following up what Mr. Dulles said about the angle of declination, the wound that came through the President's collar, you said was consistent between the same bullet. I just wondered whether under all the circumstances that you know about the President's head wound on the top that would also be consistent with a wound in Governor Connally's body?

Dr. SHAW. On the chest, yes; I am not so sure about the wrist. I can't quite place where his wrist was at the time his chest was struck.

Mr. McCLOY. Now perhaps this is Dr. Gregory's testimony, that is the full description of the wrist wound, that would be his rather than your testimony?

Dr. SHAW. I think he could throw just as much light on it as I could. And more in certain aspects.

Mr. McCLOY. It did hit bone?

Dr. SHAW. Obviously.

Mr. McCLOY. And there must have been considerable diminution in the velocity of the bullet after penetrating through the wrist?

Dr. SHAW. Yes.

Mr. DULLES. The wound inflicted on it, the chest wound on Governor Connally, if you move that an inch or two, 1 inch or the other, could that have been lethal, go through an area that could easily have been lethal?

Dr. SHAW. Yes; of course, if it had been moved more medially it could have struck the heart and the great vessels.

Mr. McCLOY. Let me ask you this, Doctor, in your experience with gunshot wounds, is it possible for a man to be hit sometime before he realizes it?

Dr. SHAW. Yes. There can be a delay in the sensory reaction.

Mr. McCLOY. Yes; so that a man can think as of a given instant he was not hit, and when actually he could have been hit.

Dr. SHAW. There can be an extending sensation and then just a gradual building up of a feeling of severe injury.

Mr. McCLOY. But there could be a delay in any appreciable reaction between the time of the impact of the bullet and the occurrence?

Dr. SHAW. Yes; but in the case of a wound which strikes a bony substance such as a rib, usually the reaction is quite prompt.

Mr. McCLOY. Yes.

Dr. SHAW. Yes.

Mr. McCLOY. Now, you have indicated, I think, that this bullet traveled along, hit and traveled along the path of the rib, is that right?

Dr. SHAW. Yes.

Mr. McCLOY. Is it possible that it could have not, the actual bullet could not have hit the rib at all but it might have been the expanding flesh that would cause the wound or the proper contusion, I guess you would call it on the rib itself?

Dr. SHAW. I think we would have to postulate that the bullet hit the rib itself by the neat way in which it stripped the rib out without doing much damage to the muscles that lay on either side of it.

Mr. McCLOY. Was—up until you gave him the anesthetic—the Governor was fully conscious, was he?

Dr. SHAW. I would not say fully, but he was responsive. He would answer questions.

Mr. McCLOY. I think that is all I have.

The CHAIRMAN. I have no questions of the doctor.

Mr. DULLES. There were no questions put to him that were significant as far as our testimony is concerned?

Dr. SHAW. No; we really don't have to question him much. Our problem was pretty clearcut, and he told us it hurt and that was about his only response as far as—

Senator COOPER. Could I ask you a question, doctor?

I think you said from the time you came into the emergency room and the time you went to the operating room was about 5 minutes?

Dr. SHAW. Yes; it was just the time that it took to ask a few simple questions, what has been done so far, and has the operating room been alerted, and then I went out and talked to Mrs. Connally, just very briefly, I told her what the problem was in respect to the Governor and what we were going to have to do about it and she said to go ahead with anything that was necessary. So this couldn't have taken much more than 5 minutes or so.

Mr. DULLES. Did you say anything or did anyone say anything there about the circumstances of the shooting?

Dr. SHAW. Not at that time.

Mr. DULLES. Either of Governor Connally or the President?

Dr. SHAW. Not at that time. All of our conversation was later.

Mr. DULLES. Was the President in the same room?

Dr. SHAW. No.

Mr. DULLES. Did you see him?

Dr. SHAW. I only saw his shoes and his feet. He was in the room immediately opposite. As I came into the hallway, I would recognize that the President was on it, in the room to my right. I knew that my problem was concerned with Governor Connally, and I turned and went into the room where I saw that he was.

Mr. DULLES. Did you hear at that time or have any knowledge, of a bullet which had been found on the stretcher?

Dr. SHAW. No; this was later knowledge.

Mr. DULLES. When did you first hear that?

(At this point Senator Russell entered the hearing room.)

Dr. SHAW. This information was first given to me by a man from the Secret Service who interviewed me in the office several weeks later. It is the first time I knew about any bullet being recovered.

Senator COOPER. I think, of course, it is evident from your testimony you have had wide experience in chest wounds and bullet wounds in the chest.

What experience have you had in, say, the field of ballistics? Would this experience—you have been dealing in chest wounds caused by bullets—have provided you knowledge also about the characteristics of missiles, particularly bullets of this type?

Dr. SHAW. No; Senator. I believe that my information about ballistics is just that of an average layman, no more. Perhaps a little more since I have seen deformed bullets from wounds, but I haven't gone into that aspect of wounds.

Senator COOPER. In the answers to the hypothetical questions that were addressed to you, based upon the only actual knowledge which you could base that answer, was the fact that you had performed the operation on the wound caused in the chest, on the wound in the chest?

Dr. SHAW. That is true. I have seen many bullets that have passed through bodies or have penetrated bodies and have struck bone and I know manners from which they are deformed but I know very little about the caliber of bullets, the velocity of bullets, many things that other people have much more knowledge of than I have.

Senator COOPER. That is all.

The CHAIRMAN. Thank you very much, Dr. Shaw.

JFK EXHIBIT F-71

N ASSASSINATIONS

NAME Dr. Robert Shaw Date 11 9 77 Time 1:00
 Address 7403 Villanova Dallas County Institute of
 Place Forensic Sciences, Dallas,
Dallas, Texas 75225 214 691 6136 -- 214 752 3752
 Date of Birth: 11/15/05
 Interview:

Dr. Shaw arrived at the trauma room in which Governor Connally was being treated five minutes past his arrival. The residents (Drs. Boland, Duke, Giesecke) had done an excellent job.

The Governor's front chest had 5 cm. (obvious) wound of exit - paradoxical motions of chest were evident. There was a smaller tunneling wound in the back/chest. The bullet struck the 5th rib in a tangential way pushing it out, causing a fracture at a point farther up the rib (like a tree limb breaking from pressure exerted near its end). Bullet and rib fragments exited out the front of the Governor causing the larger exit hole.

Shaw said the lower 2/3ds of the Governor's lower lung lobe was like liver, full of blood and holes caused by secondary (bone) missile fragments. There was a rent in the latissimus dorci.

The rear entrance wound was not 3 cm as indicated in one of the operative notes. It was a puncture-type wound, as if

(continued)

Interviewer _____
 (Signature)

 Andy Purdy
 (Typed)

Date Transcribed 11/17/77 by IJ
 (ir)

a bullet had struck the body at a slight declination (i.e. not at a right angle). The wound was actually approximately 1½ cm. The ragged edges of the wound were surgically cut away, effectively enlarging it to approximately 3 cm.

Wrist: The wrist wound had been described as a "comminuted" fracture, meaning (according to Dr. Shaw) it was "compounded" (I.E. in more than two pieces). The work on the wrist was primarily done by Dr. Gregory (deceased).

Dr. Shires did the work on the thigh wound.

In response to Dr. Petty's questions, Dr. Shaw provided the following:

- 1) The bullet entering the back did not strike dead on, hitting instead on a decline.
- 2) The entrance wound was olvode (see Dr. Shaw's drawing attached).
- 3) The shape of the entrance wound was consistent with a missile striking in a slightly downward trajectory. It is Dr. Shaw's opinion that the wound was not caused by a tumbling bullet (an inference drawn, explicitly, from his belief that a tumbling bullet would not have had sufficient force to cause the remainder of the Governor's wounds).
- 4) Dr. Shaw believes that the bullet which hit the Governor had not struck any other objects because of his conclusion that the bullet was not tumbling.

He does note that the entrance wound was longer along the vertical axis.

- 5) The bullet did not traverse the thorax; it was essentially "...a chest wall wound ...," with much of the damage to the Governor being caused by a "blast-like" effect which resulted from the bullet tangentially striking the fifth rib, turning pieces of it into secondary missiles.
- 6) He described the chest wound as a "slap wound" exerting an inward force on the body from the secondary fragments.
- 7) The blood found in the lung's lower lobe was from a tear in the middle lobe and contusion from the slapping effect of the bullet, as well as from the penetration of multiple rib fragments ("...it was very much like a blast injury ...").
- 8) The bullet did not traverse the lung; there was essentially a chest wall injury which involved the lung because of a blast injury effect ("...there was a bronchial tear in the middle lobe in addition to the rent...").

Dr. Shaw examined the original Connally X-rays and the enhanced copies. He could not detect any metal fragments in the chest or in the femur (thigh bone). The only metal fragment he denoted was a small one in the subcutaneous tissue in

in the thigh. He did notice the rib fracture in the chest X-ray, as well as rib pieces.

Dr. Shaw indicated that the enhanced X-ray of the fragment in the thigh convinced him that the object was metal because it has greater density than bone and the existence of a hook-like end of the object is more consistent with metallic than with bone characteristics.

Regarding press accounts that he felt the metal fragment was too heavy to have come from C.E.399, Dr. Shaw said he is not qualified to speculate as to the actual size or weight of the fragment in the thigh or those in the wrist (even though he admittedly did so before the Warren Commission 4 H 113). He did say he has never been satisfied that the bullet found on Governor Connally's stretcher had caused all of the Governor's wounds.

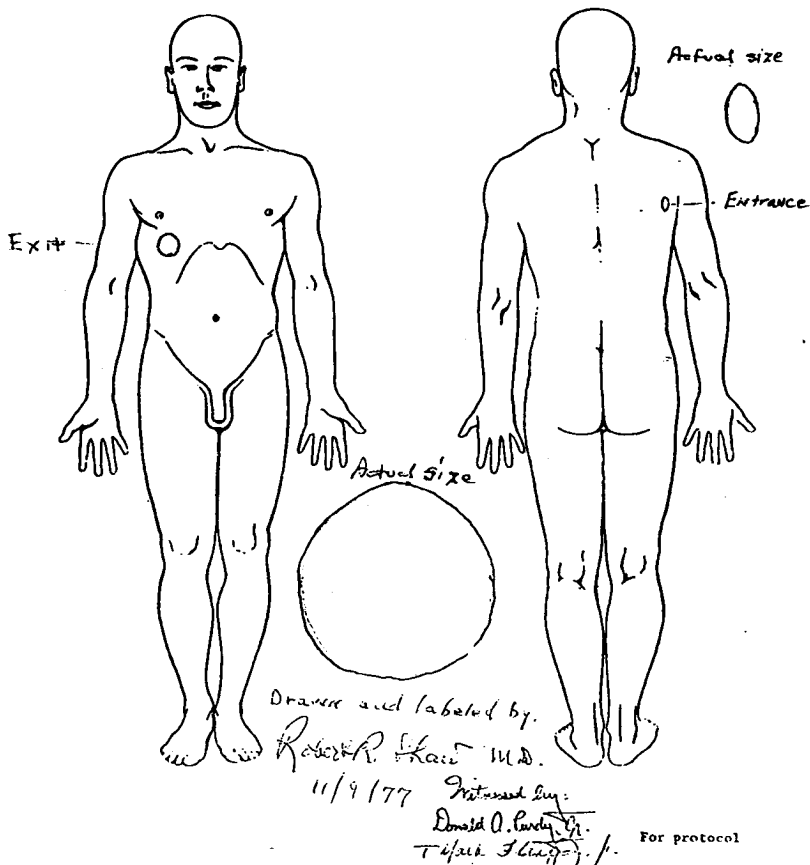
Shaw believes the "...bullet found on the limousine floor was more likely the one which went through Connally." He believes the bullet that went through the President's neck may have gotten caught in the Governor's clothing and another bullet struck the Governor causing his wounds.

Regarding the wrist wound, Shaw said he first thought the bullet entered through the volar aspect and exited the dorsum; he was later convinced by Dr. Gregory (and currently believes) that the exact opposite was the case.

THE SOUTHWESTERN INSTITUTE OF FORENSIC SCIENCES
AT DALLAS

Name _____ Autopsy No. _____

Color _____ Age _____ Date _____



Mr. KLEIN. Doctor, do you recognize those reports?

Dr. BADEN. Yes, these are reports from the testimony of Dr. Shaw, a thoracic surgeon, a chest doctor, who operated on Governor Connally at Parkland Hospital, made before the Warren Commission, and subsequent reports of interviews by the staff members and Dr. Petty of the medical panel who interviewed Dr. Shaw recently.

Mr. KLEIN. Doctor, what did the panel learn from those reports with respect to the entrance and exit wounds of the back of the Governor?

Dr. BADEN. There was an entrance perforation, according to the interpretation of the doctors who operated on Governor Connally, in the upper right back region just next to the top of the armpit area, and the bullet pathway proceeded from back to front, downward, causing extensive fractures of the fifth rib of the Governor

and exited in a large irregular jagged typical exit perforation 1 inch below the right nipple.

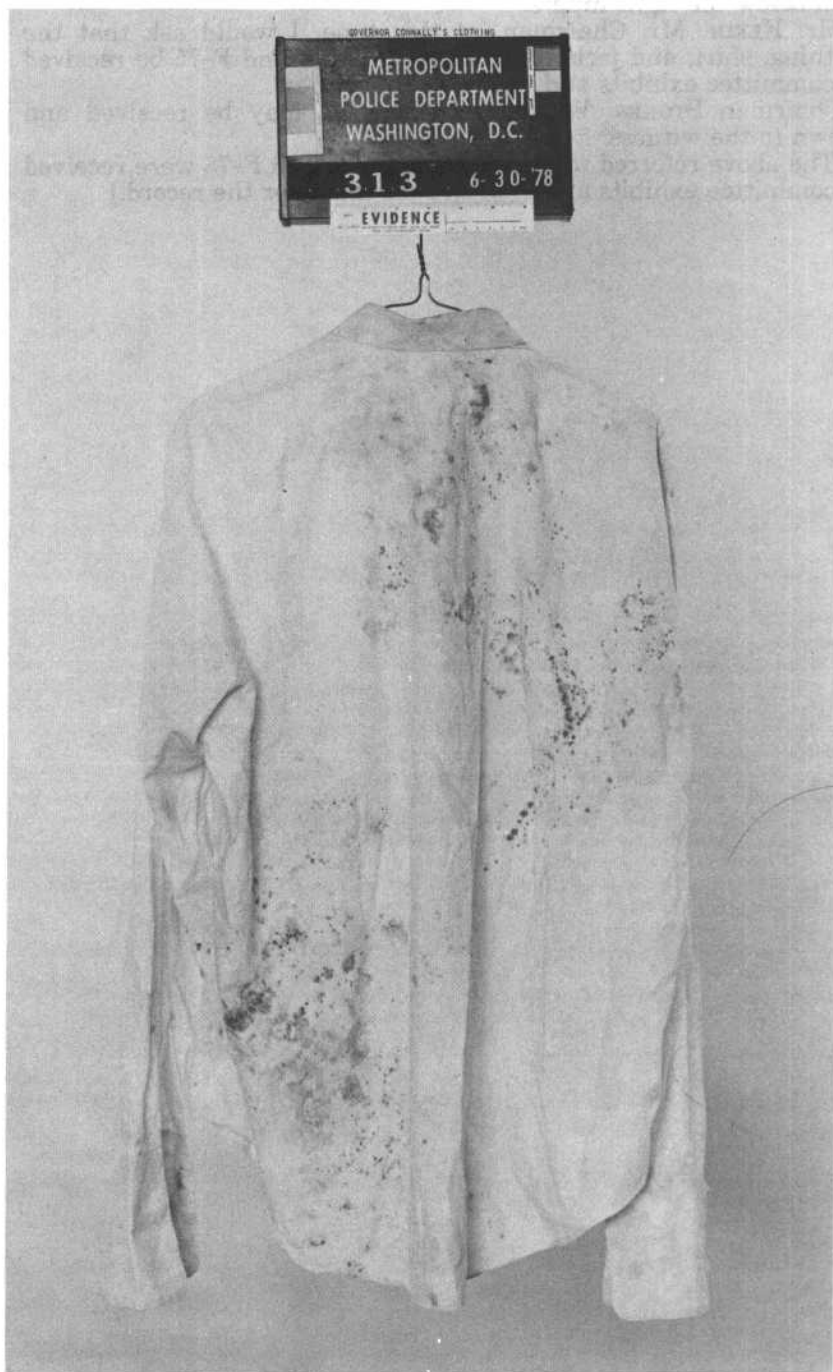Mr. KLEIN. Mr. Chairman, at this time, I would ask that the clothing, shirt, and jacket, marked JFK F-74 and F-75 be received as committee exhibits and shown to the witness.

Chairman STOKES. Without objection, it may be received and shown to the witness.

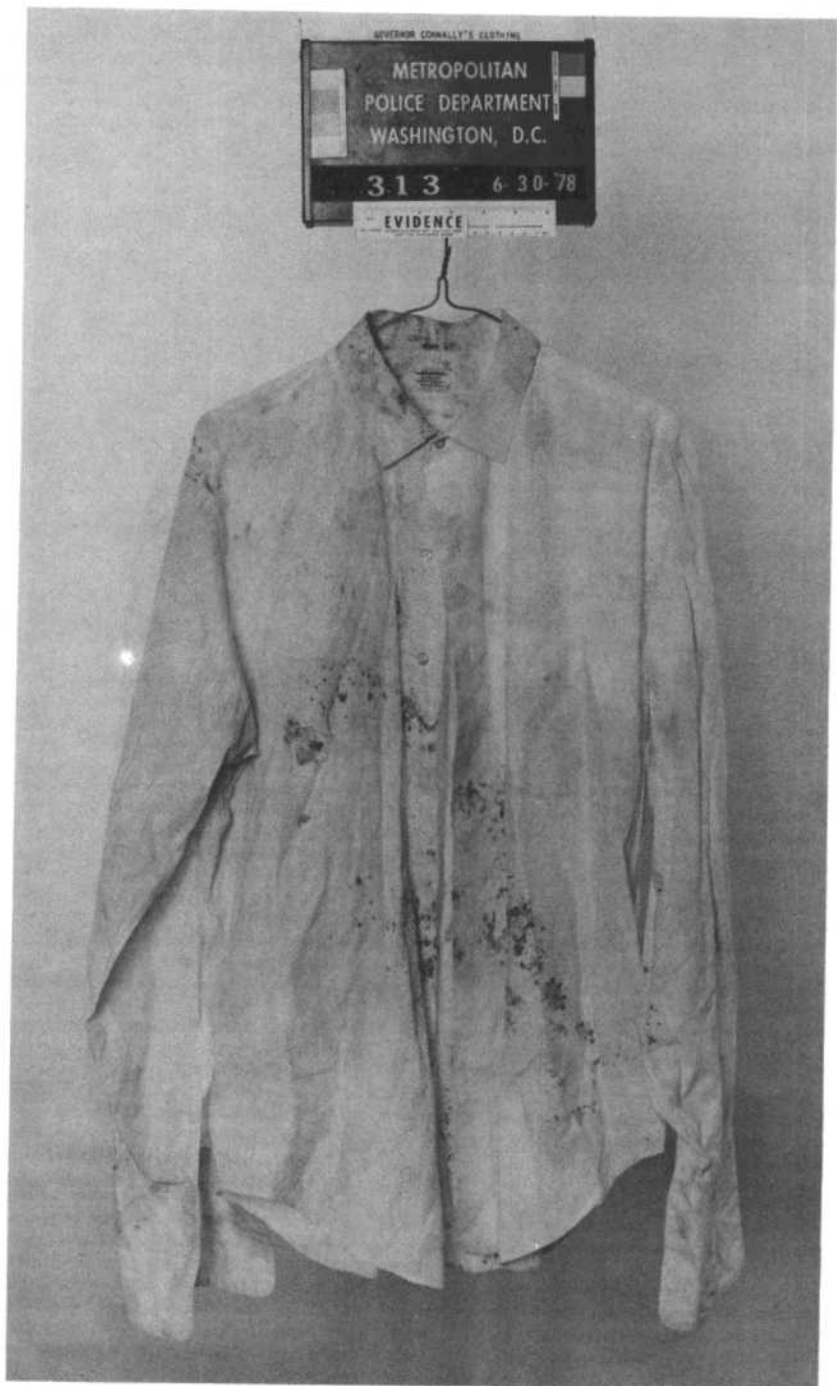[The above referred to JFK exhibits F-74 and F-75 were received as committee exhibits and photographs made for the record.]

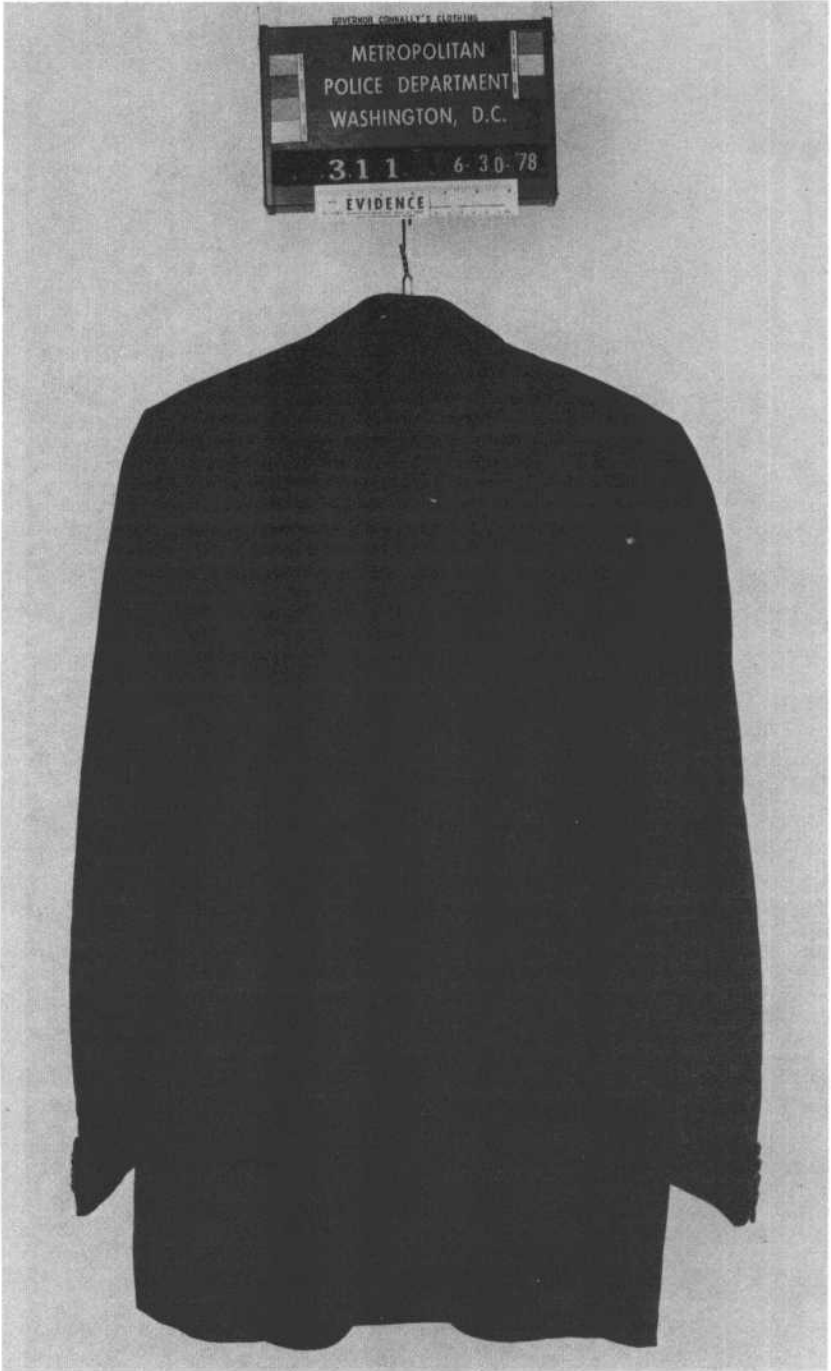
278

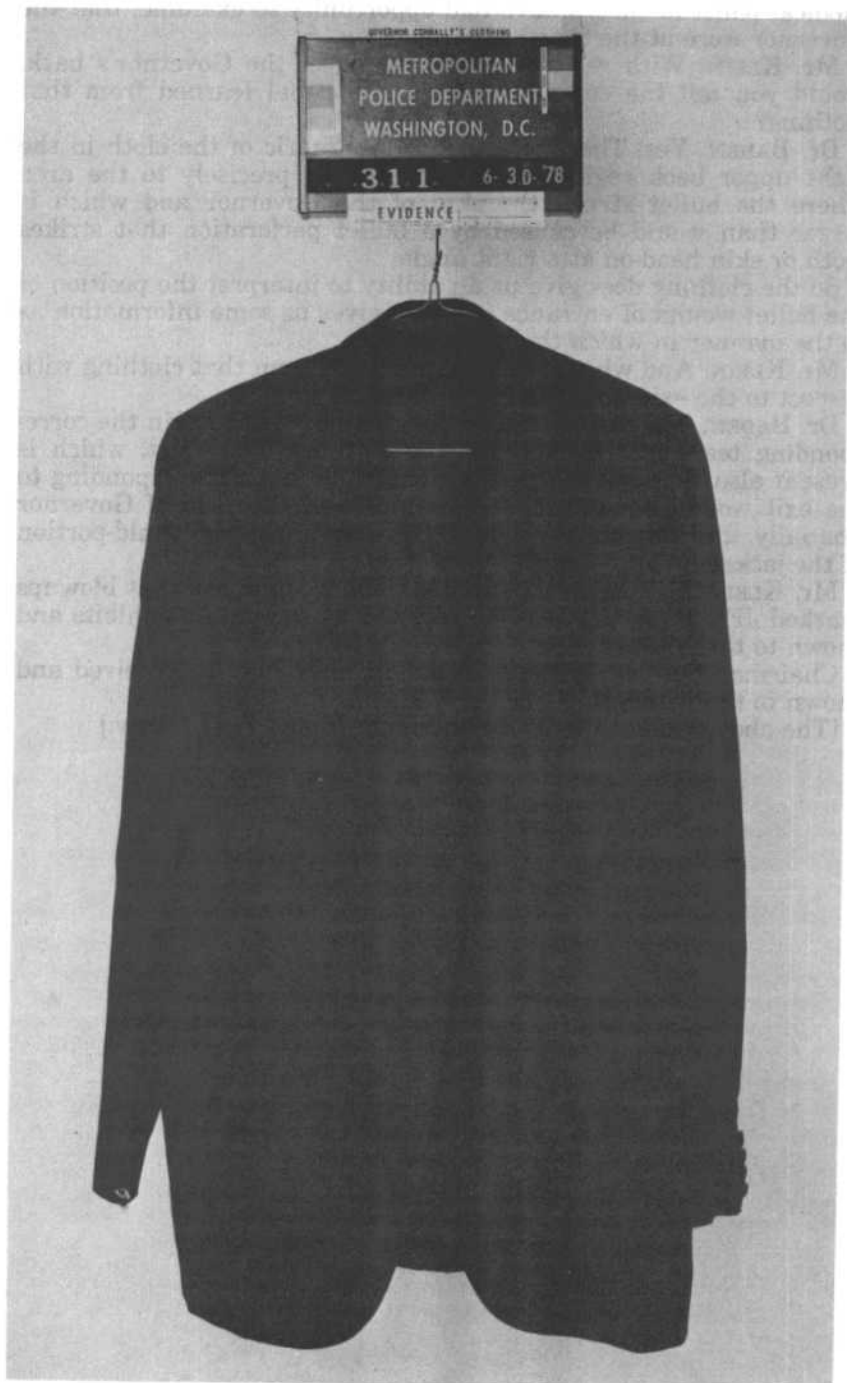
JFK EXHIBIT F-74



279







Dr. BADEN. This is the clothing of Governor Connally that the medical panel members have had opportunity to examine, that the Governor wore at the time of the shooting.

Mr. KLEIN. With respect to the wound of the Governor's back, would you tell the committee what the panel learned from that clothing?

Dr. BADEN. Yes. There is a tear in the fabric of the cloth in the right upper back region which corresponds precisely to the area where the bullet struck the skin of the Governor and which is larger than would be caused by a bullet perforation that strikes cloth or skin head-on at a right angle.

So the clothing does give us an ability to interpret the position of the bullet wound of entrance and also gives us some information as to the manner in which the bullet struck.

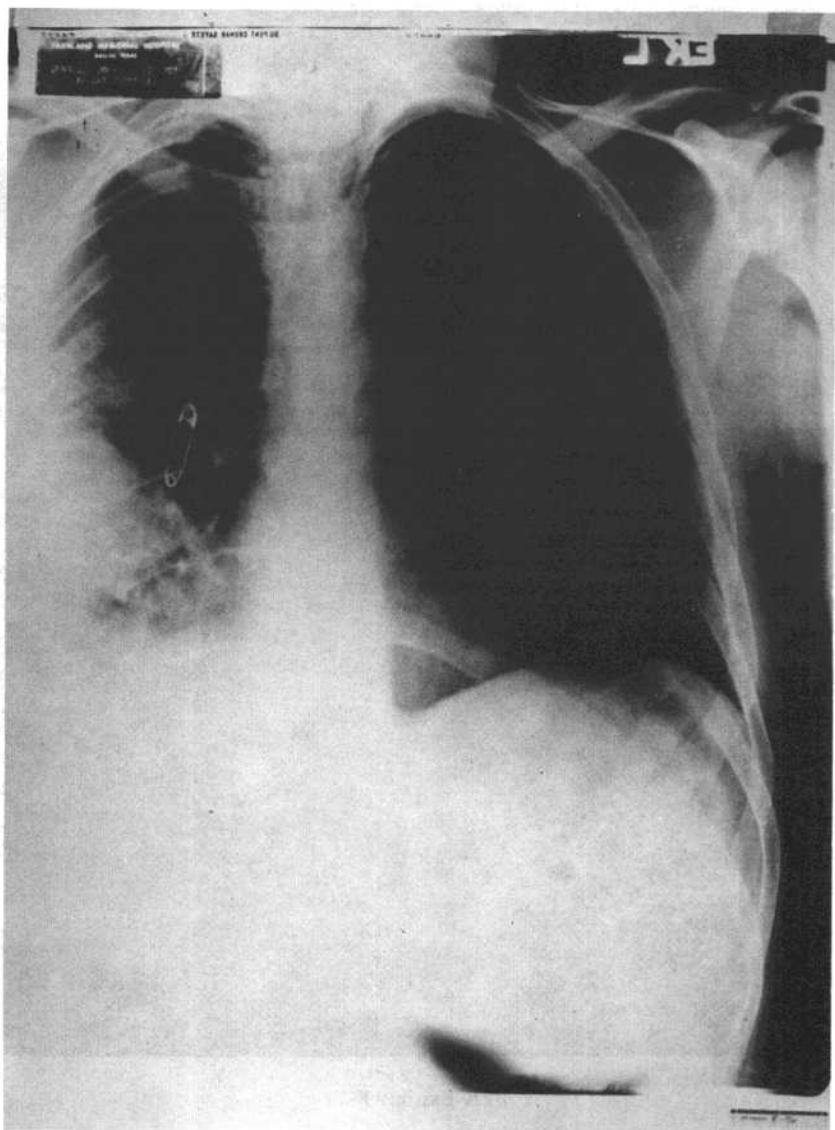
Mr. KLEIN. And what did the panel learn from that clothing with respect to the exit wound?

Dr. BADEN. The exit wound on the clothing—and again the corresponding tears in the fabric of the clothing. The shirt, which is present also, does show a perforation of the fabric corresponding to the exit wound beneath the right nipple of the skin of Governor Connally, and this corresponds to the tear in the right mid-portion of the jacket.

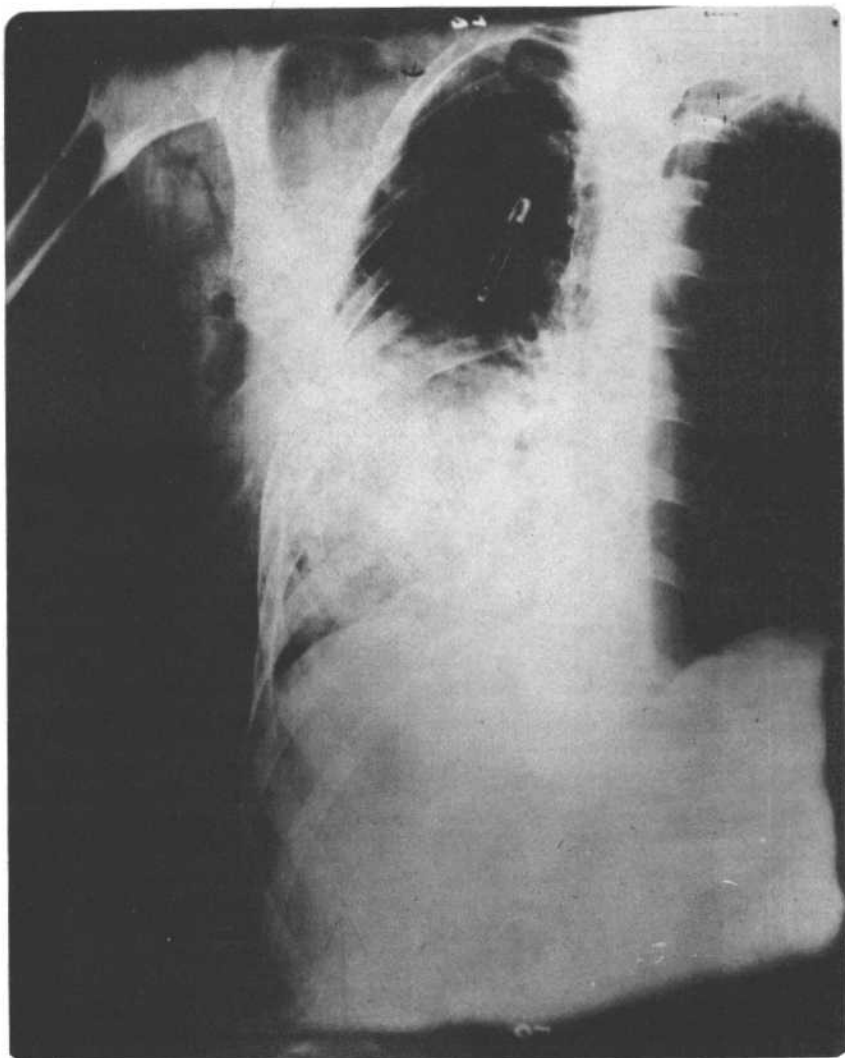
Mr. KLEIN. Mr. Chairman, at this time, I would ask that blowups marked JFK F-76 and F-77 be received as committee exhibits and shown to the witness.

Chairman STOKES. Without objection, they may be received and shown to the witness.

[The above referred to JFK exhibits F-76 and F-77 follow:]



JFK EXHIBIT F-76



JFK EXHIBIT F-77

Mr. KLEIN. Doctor, do you recognize these blowups?

Dr. BADEN. Yes; I do. They are photographic enlargements of two of the X-rays taken of the chest of Governor Connally at Parkland Memorial Hospital.

Mr. KLEIN. Doctor, did the panel have an opportunity to examine these X-rays?

Dr. BADEN. Yes.

Mr. KLEIN. And from these X-rays did the panel determine whether there were injuries consistent with a bullet passing through the Governor?

Dr. BADEN. Yes. There were X-rays that the panel was able to review that show fractures of the fifth rib, as described by the

surgeons, and no missile, no bullet projectile, nor any evidence of metal present on the X-ray.

Mr. KLEIN. And was there any indication that the bullet was still in the Governor, or did the X-ray show the bullet had passed through?

Dr. BADEN. There was no evidence of any missile or bullet present on the X-rays taken of the Governor at the time of admission to Parkland Hospital.

Mr. KLEIN. Did the panel have an opportunity to examine the reports of Dr. Reynolds?

Dr. BADEN. Yes, sir.

Mr. KLEIN. And who is Dr. Reynolds?

Dr. BADEN. Dr. Reynolds was a radiologist, X-ray physician at Parkland Hospital, who made reports on various X-rays taken of Governor Connally during his stay and treatment at the hospital.

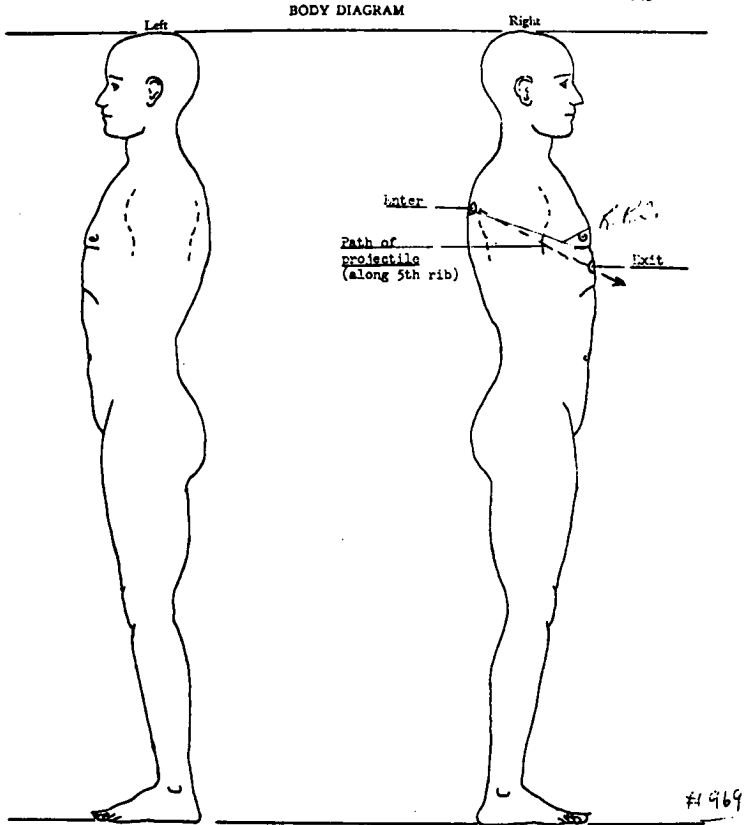
Mr. KLEIN. And were his reports consistent with what you have told us with regard to the bullet which entered the Governor's back?

Dr. BADEN. Yes. He does describe on the X-rays extensive injury to the rib of the Governor, and to the lung.

Mr. KLEIN. Mr. Chairman, at this time, I would ask that the diagram marked JFK F-81 be received as a committee exhibit and shown to the witness.

Chairman STOKES. Without objection, it may be received and shown to the witness.

[The above referred to JFK exhibit F-81 follows:]



JFK EXHIBIT F-81

Mr. KLEIN. Doctor, do you recognize that diagram?

Dr. BADEN. Yes, I do. This is an enlargement of a diagram prepared by the surgeons at Parkland Hospital for the Warren Commission, at which time this material was discussed.

Mr. KLEIN. What does that diagram show?

Dr. BADEN. The diagram is an outline of an individual in an erect posture, so-called anatomic position, showing a gunshot wound of entrance indicated in the right upper back, and an exit wound noted below the right nipple, with a straight pathway drawn between.

There are also notations by Dr. Shires, who I believe the initials are of Dr. Shires, who placed the track slightly higher to correspond to the exit being 1 inch beneath the nipple. This track is meant to correspond to the fifth rib, which is the only rib that was injured by the bullet path.

Mr. KLEIN. Did the panel agree with the locations of the entry and exit wounds as well as the path of the bullet as depicted by that diagram?

Dr. BADEN. Yes, sir; in general the panel did agree that there was an entrance wound of the upper back exiting below the nipple and a downward track between.

Mr. KLEIN. Doctor, with respect to the wound of the Governor's wrist, did the panel have an opportunity to read the reports of Dr. Gregory and to read his Warren Commission testimony?

Dr. BADEN. Yes, sir.

Mr. KLEIN. And why wasn't the panel able to speak with Dr. Gregory?

Dr. BADEN. Dr. Gregory is deceased. Panel members did talk, and the staff members did talk, with Dr. Shaw who operated on the chest, and with other doctors from Parkland Hospital, but did not have an opportunity to speak with Dr. Gregory.

Mr. KLEIN. In reading the reports and medical records of Dr. Gregory, what did the panel learn with respect to the wound of the Governor's wrist?

Dr. BADEN. The panel learned that there was a gunshot perforation of the thumb side of the forearm about 1 inch above the wrist, which on examination was finally determined to be the point of entrance, and that the bullet did exit through the front of the wrist at the crease of the wrist.

Mr. KLEIN. Directing your attention to the clothing already received as an exhibit, what did the panel learn from the clothing with respect to the wound of the Governor's wrist?

Dr. BADEN. On the clothing, including the suit coat and the shirt, which has French cuffs and is longer than the coat sleeve, there is a perforation of the fabric of the cloth that corresponds with the thumb side of the lower portion of the forearm of the Governor. The tear in the fabric is wide and irregular and the panel concluded that this was made by a bullet reentering into the wrist.

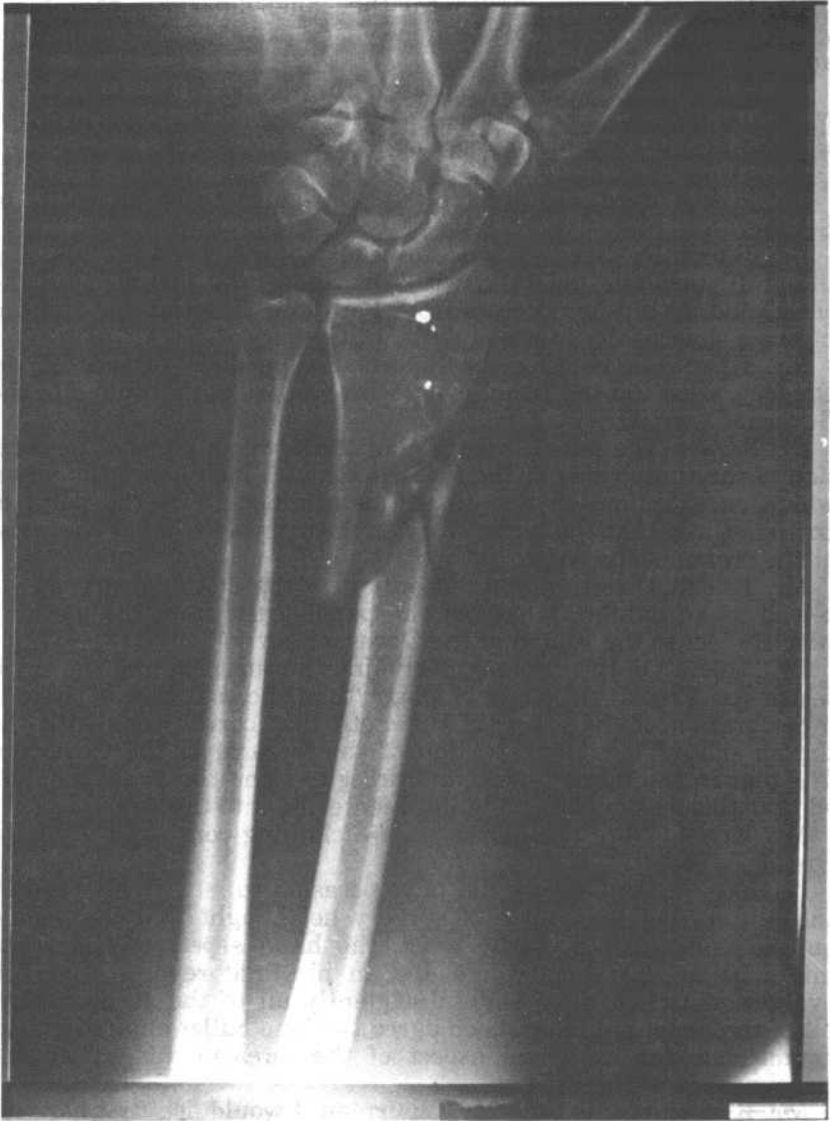Mr. KLEIN. Were the marks on the clothing consistent with Dr. Gregory's reports?

Dr. BADEN. Dr. Gregory did have occasion to modify his reports. Initially during the course of surgery he thought that the wound on the undersurface of the wrist, the hand aspect of the wrist, might be an entrance wound, but in his final reports after full evaluation Dr. Gregory and subsequently all of the surgeons and all of the panel pathologists do agree that the bullet entered on the thumb side top or dorsal aspect of the forearm and exited the undersurface of the wrist.

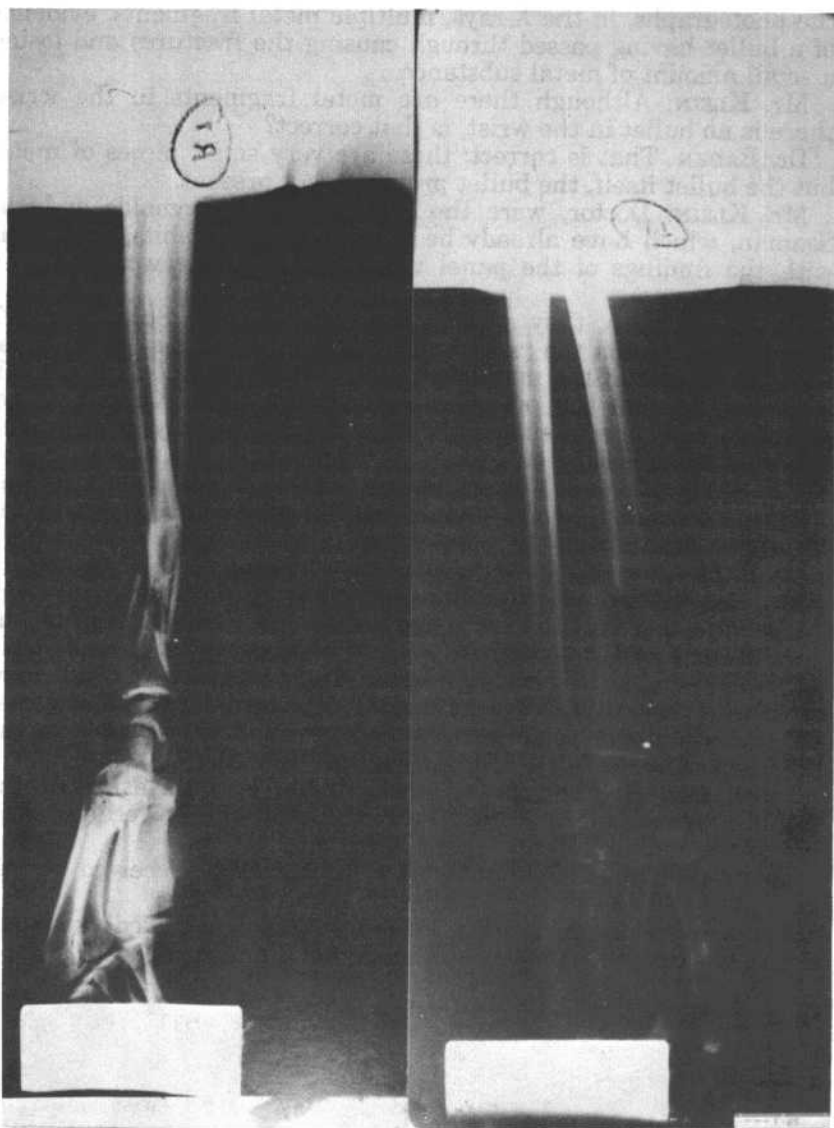
Mr. KLEIN. At this time Mr. Chairman, I would ask that blowups marked JFK F-84 and F-85 be received as committee exhibits and shown to the witness.

Chairman STOKES. Without objection, they may be received at this point.

[The above referred to JFK exhibits F-84 and F-85 follow.]



JFK EXHIBIT F-84



JFK EXHIBIT F-85

Mr. KLEIN. Doctor, do you recognize these blowups?

Dr. BADEN. Yes, these are enlargements of X-rays provided the panel of Governor Connally's right wrist taken at Parkland Hospital before any surgery was performed. These show extensive fractures of one of the long bones of the forearm, the radius bone, approximately 1 inch above the wrist. The wrist itself is composed of many small bones as can be seen here and is normal. There are fractures of one bone, the radius bone, just before it enlarges to articulate or meet with the wrist bones, and there are present in

the photographs, in the X-rays, multiple metal fragments, evidence of a bullet having passed through causing the fractures and losing a small amount of metal substance.

Mr. KLEIN. Although there are metal fragments in the wrist, there is no bullet in the wrist, is that correct?

Dr. BADEN. That is correct; these are very small pieces of metal but the bullet itself, the bullet proper, is not present.

Mr. KLEIN. Doctor, were the reports of Dr. Reynolds and Dr. Seaman, which have already been received as exhibits, consistent with the findings of the panel with respect to the wound of the wrist?

Dr. BADEN. Yes; they support the panel's view. Subsequent X-rays of the wrist in the process of healing after surgery does reveal that the largest of the metal fragments although still a very small fragment seen in the preoperative blowup of the X-ray, was removed at the time of surgery. This was subsequently given to the Archives for preservation.

Mr. KLEIN. Doctor, I direct your attention to the wound of the Governor's thigh. Did the panel have an opportunity to read the reports of Dr. Shires?

Dr. BADEN. Yes, sir.

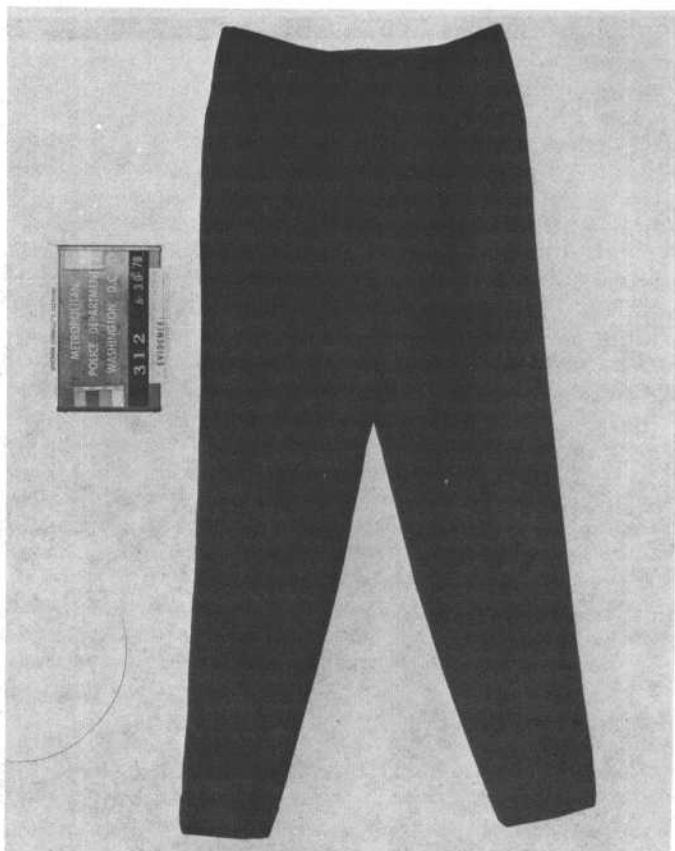
Mr. KLEIN. And could you tell us what the panel learned from the reports of Dr. Shires with respect to the wound of the thigh?

Dr. BADEN. We reviewed Dr. Shires' reports and staff and medical panel members did have an opportunity to speak and interview Dr. Shires recently. We concluded from available evidence that there was a single perforating gunshot wound of entrance in the inner aspect of the left thigh of Governor Connally.

Mr. KLEIN. Mr. Chairman, at this time, I would ask that the clothing deemed marked JFK F-88, the trousers, be received as a committee exhibit?

Chairman STOKES. Without objection, it may be received at this point.

[The above referred to JFK exhibit F-88 was received as a committee exhibit and a photograph made for the record.]



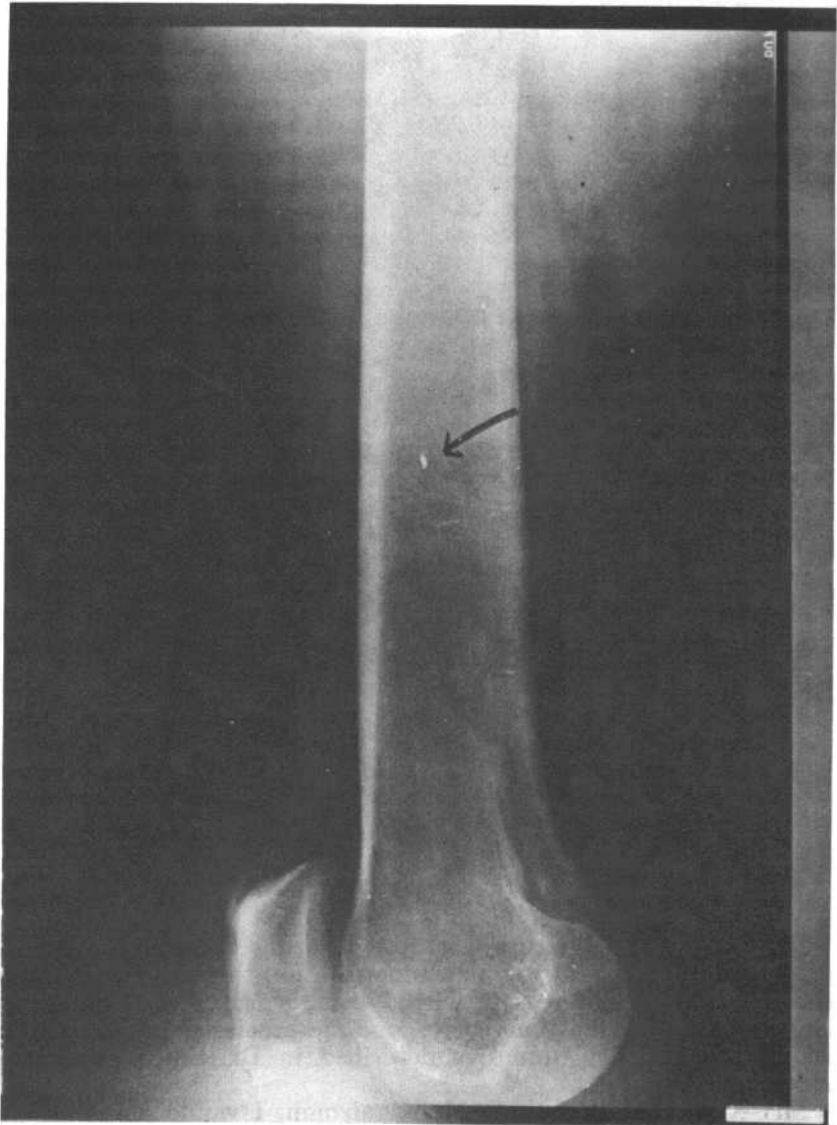
JFK EXHIBIT F-88

Dr. BADEN. The trousers worn by Governor Connally have been preserved and show the entrance perforation through the fabric of the left inner thigh region, with typical features of a round entrance bullet perforation corresponding precisely in location to where the gunshot wound is described in Dr. Shires' operative report.

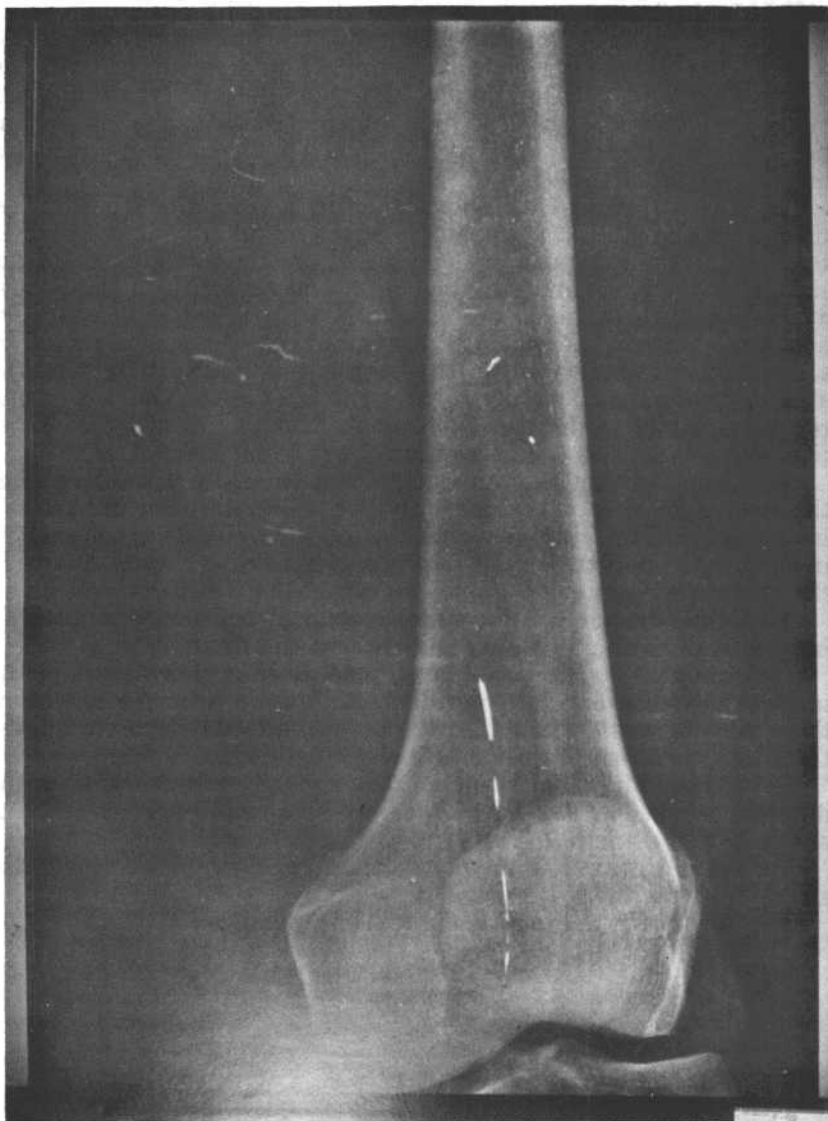
Mr. KLEIN. At this time, Mr. Chairman, I would ask that the blowups, JFK F-89 and F-90, be received as committee exhibits.

Chairman STOKES. Without objection they may be received.

[The above referred to JFK exhibits F-89 and F-90 follow:]



JFK EXHIBIT F-89



JFK EXHIBIT F-90

Mr. KLEIN. Do you recognize those blowups, Doctor?

Dr. BADEN. Yes, Mr. Klein, these are enlargements of the X-rays of Governor Connally's thigh that were taken at the time of admission to Parkland Hospital.

Mr. KLEIN. What did the panel learn from those X-rays?

Dr. BADEN. The panel learned that there was no bullet nor significant portion of bullet present in the thigh; this was also confirmed by the fact that the surgeons did explore the wound in the thigh surgically and found no bullet.

This is the lower thigh bone in the blowup. This is the knee area and the left thigh of Governor Connally. The blowup on your left is a side view showing a small piece of white irregularity with an arrow which is on the original X-rays, put there by treating physicians in Parkland Hospital and interpreted by some physicians initially and in testimony to the Warren Commission as being metal from a bullet within the thigh bone itself.

The direct frontal view shows the thigh from the front rather than from the side. This shows the same metal fragment which in the interpretation of the medical panel members, the panel's consultant radiologists and Dr. Reynolds, who reported on the X-rays at Parkland Hospital, is not in the bone but is immediately beneath the skin on the inside of the thigh. What was interpreted by some doctors as being within the bone is really an artifact, that is, a marking produced by dirt or a scratch, et cetera, and does not represent injury to the bone. This is an enhanced LogEtronic X-ray that assisted us, and is clearer than the original X-ray.

We concluded that the bullet did enter the skin of the thigh but that it was a spent bullet and it did not penetrate more than a half inch or so into the skin, and that in fact the bullet was not present in the thigh when treatment was provided to Governor Connally in the operating room.

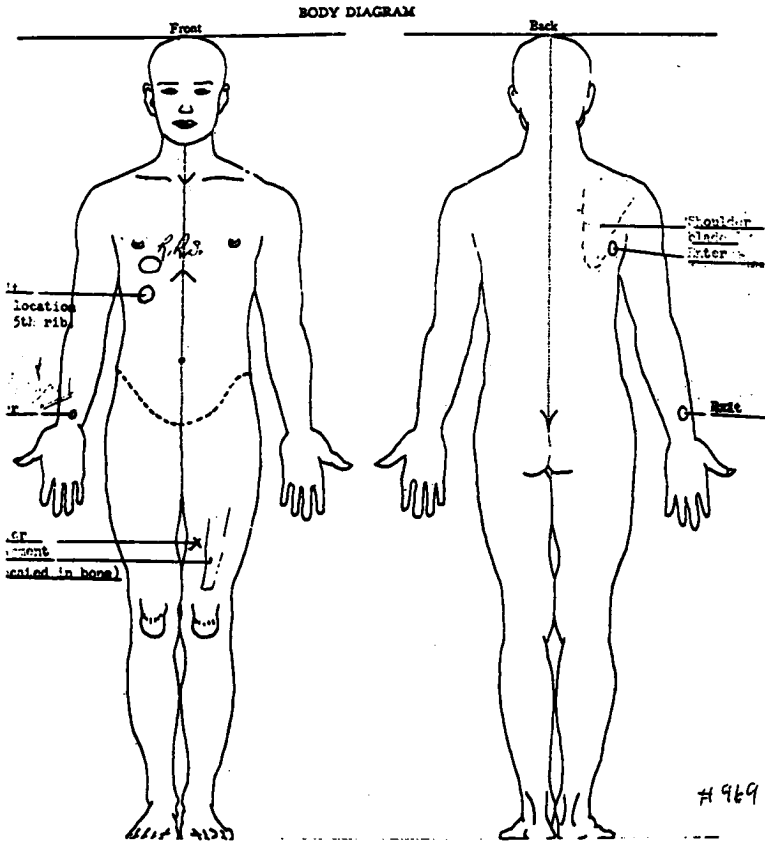
Mr. KLEIN. Doctor, did the panel reach any conclusion as to what happened to the bullet which had entered the thigh?

Dr. BADEN. Yes, the panel concluded after reviewing all of the medical evidence and other evidence and circumstances as to how the Governor was treated, that the bullet had partially entered, the thigh and then had dropped out.

Mr. KLEIN. Mr. Chairman, at this time, I would ask that the diagram marked JFK F-73 be received as a committee exhibit and shown to the witness.

Chairman STOKES. Without objection, it may be received and shown to the witness.

[The above-referred-to JFK exhibit F-73 follows:]



Commission Exhibit No. 679

JFK EXHIBIT F-73

Mr. KLEIN. Doctor, do you recognize that diagram?

Dr. BADEN. Yes; I do. This is an enlargement of a diagram prepared by the surgeons at Parkland Hospital for the Warren Commission, at which time this material was discussed.

Mr. KLEIN. What does the diagram show?

Dr. BADEN. The diagram is an anterior-posterior outline of an individual in an erect position, so-called anatomic position, showing gunshot wounds to the chest, wrist, and thigh.

Mr. KLEIN. Did the panel agree with the locations of the entry and exit wounds?

Dr. BADEN. Yes; the panel generally agreed.

Mr. KLEIN. Doctor, I have a few more questions but I think you can sit down now, you might be more comfortable.

Doctor, to sum up for a moment. On the basis of foregoing evidence, the X-rays taken by the surgeons in Parkland Hospital, the medical records and interviews with the surgeons from Parkland Hospital, the condition of the Governor's clothing, and the reports of the doctors who examined the X-rays at the request of the panel, did the panel unanimously conclude, first, that the Governor received an entry wound of his right lateral back and the bullet exited from his right chest?

Dr. BADEN. Yes, all the panel members so concluded.

Mr. KLEIN. Second, did the panel unanimously conclude the Governor received an entry wound of his wrist and the bullet exited on the front surface of his right wrist?

Dr. BADEN. Yes, sir; on the hand surface of the wrist.

Mr. KLEIN. And, third, did the panel unanimously conclude that the Governor received an entry wound in his left thigh with subsequent dislodgement of the bullet?

Dr. BADEN. Yes.

Mr. KLEIN. Has the panel reached a conclusion as to whether these wounds were all caused by one bullet?

Dr. BADEN. Yes, sir. The panel did conclude that these wounds were caused by one bullet.

Mr. KLEIN. Would you please explain to the committee why the panel concluded that one bullet caused the wounds received by the Governor?

Dr. BADEN. Yes. The panel concluded that, taking into evaluation the nature of the injuries to the wrist and thigh and to the chest region, and the direction of these injuries, that a single bullet proceeding through the chest exiting below the nipple, entering the wrist in a partially spent manner, not at full force which would have caused much greater damage to the wrist—exiting the wrist and then reentering the left thigh, is all consistent with a single gunshot track, and the panel has seen no other reasonable evidence to support anything but a single track through the Governor.

Mr. KLEIN. Did the examination of the wound to the wrist and thigh lead the panel to conclude that the bullet which entered the wrist and then entered the thigh had been slowed up by something prior to hitting the wrist and prior to hitting the thigh?

Dr. BADEN. Yes, that is, the bullet striking the thigh was an obviously spent bullet that must have gone through other structures or struck something before striking the thigh or else it would have caused a massive defect in the thigh and exited the thigh.

The bullet striking the wrist also was produced by a bullet that had lost full power and it was the conclusion of the panel that it had struck something before striking the wrist and it was the conclusion of the panel the most reasonable area to have struck before striking the wrist and considering the position of the Governor seated at the time of the shooting, that it did indeed strike the back and exit the chest. And the path lines up for all three tracks.

Mr. KLEIN. Doctor, you have also testified that the panel unanimously concluded that a bullet entered the President's upper right back and exited from the front of his neck. Did the panel reach a conclusion as to whether the same bullet which entered the President's upper right back could have then exited from the front of

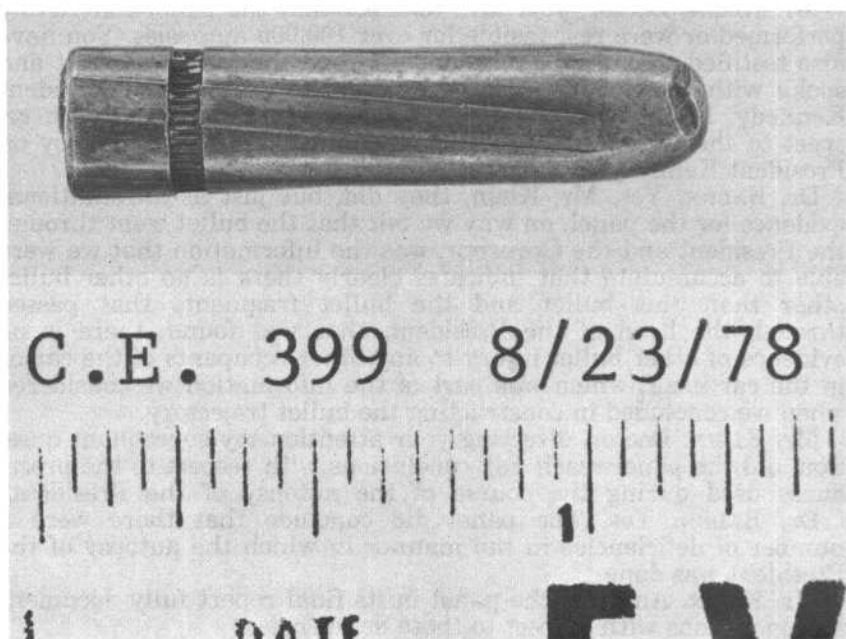his neck and struck Governor Connally and caused the wounds that he received?

Dr. BADEN. Yes; the panel concluded, based on the enlarged nature of the entrance perforation in the Governor's back, that the bullet was wobbling when it struck him and had to have struck something before striking the Governor; that this entrance perforation of the Governor's back could have resulted from a missile that had come through the neck of the President on the basis of the autopsy findings alone; that in taking other evidence into consideration, such as the position of the President and the position of the Governor in the car, the findings are entirely consistent with a single bullet exit exiting the front of the President's neck and re-entering in the back of the Governor.

Mr. KLEIN. Mr. Chairman, I would ask that this little container and its contents be deemed marked "JFK Exhibit F-95", received as an exhibit, and shown to the witness.

Chairman STOKES. Without objection, it may be received.

[The above referred to JFK exhibit F-95 was received as a committee exhibit and a photograph made for the record.]



JFK EXHIBIT F-95

Mr. KLEIN. Doctor, do you recognize the contents of that container?

Dr. BADEN. Yes, from the label on the container and from examining the bullet, I recognize this as the Warren Commission Exhibit 399, which is a 6.5 millimeter Mannlicher Carcano bullet.

Mr. KLEIN. Did the entire panel have an opportunity to examine this bullet?

Dr. BADEN. Yes.

Mr. KLEIN. What expertise, if any, did the members of the panel have with respect to determining whether a particular bullet is consistent with having caused one or more wounds?

Dr. BADEN. The panel members in the normal course of their official duties have many occasions frequently to perform autopsies on victims of gunshot wounds and to examine missiles that cause these injuries, so that there is a great deal of experience among the panel members in examining effects of gunshot injuries and the missiles that produce them.

Mr. KLEIN. Doctor, did the panel reach a conclusion as to whether this bullet is consistent with having entered President Kennedy's upper right back, exited through the front of his neck, and entered Governor Connally and caused the wounds that the Governor received?

Dr. BADEN. Yes, the panel did conclude, all but one, Dr. Wecht, who will testify later, that this bullet is in fact consistent with having caused all of the wounds described and that in fact, this bullet is significantly flattened at one end and is not in a virgin state.

Mr. KLEIN. Doctor, you have testified that the panel collectively performed or were responsible for over 100,000 autopsies. You have also testified that the panel members read the autopsy report and spoke with the doctors who performed the autopsy on President Kennedy. Did the panel members reach any conclusions with respect to the procedures used during the course of the autopsy on President Kennedy?

Dr. BADEN. Yes, Mr. Klein, they did, but just as an additional evidence for the panel, on why we felt that the bullet went through the President and the Governor, was the information that we were able to accumulate that indicates clearly there is no other bullet other than this bullet and the bullet fragments that passed through the head of the President, that was found, there is no evidence of other bullet injury to any other occupants of the car or in the car itself, which was part of the information we considered when we concluded in constructing the bullet trajectory.

Mr. KLEIN. Doctor, directing your attention my subsequent question, did the panel reach any conclusions with respect to the procedures used during the course of the autopsy of the President?

Dr. BADEN. Yes. The panel did conclude that there were a number of deficiencies in the manner in which the autopsy of the President was done.

Mr. KLEIN. And will the panel in its final report fully document its conclusions with respect to these deficiencies?

Mr. BADEN. Yes; the panel will document its full critical analysis from the improper assumption of jurisdiction of the dead body and deficiencies in the qualifications of the pathologists who did the autopsy, to the failure of the prosecutors to contact the doctors who treated the President at Parkland Hospital and failure to inspect the clothing, to the inadequate documentation of injuries, lack of proper preservation of evidence, and incompleteness of the autopsy.

Mr. KLEIN. And in its final report will the doctors also be making recommendations as to what procedures should be utilized in the future?

Dr. BADEN. Yes, sir.

Mr. KLEIN. Thank you, Mr. Chairman, I have no further questions.

Chairman STOKES. Thank you, counsel.

Prior to recognizing the next member of the committee, the Chair would like to note the presence in the hearing room today of four gentlemen, Mr. Clarence Lyons, Mr. Marion Johnson, Mr. Michael Leahy, and Mr. William Grover. These gentlemen are employed by the National Archives and over a period of time have been extremely cooperative with this committee in furnishing and making available materials which are held in the National Archives, and they also came over last night and spent time with this committee, to a rather late hour, and are back in the hearing room this morning providing our committee with these materials. The committee wishes to thank you for the kind of cooperation that we have received from you.

The Chair at this time recognizes the gentleman from North Carolina, Judge Preyer.

Mr. PREYER. Thank you very much, Dr. Baden, for your testimony. There has been considerable controversy over the autopsies, and there has been confusion since there have been several autopsies and several panels which have worked on this and we appreciate your meticulous and painstaking testimony which, I think, goes a long way to clearing up much of the uncertainty.

Your testimony reflects the conclusions, I take it, of eight members of your panel. There is one member who dissents, in part, and who will testify later today; is that correct?

Dr. BADEN. That's correct, Mr. Preyer. All nine members do agree on the bulk of the material I presented, but Dr. Wecht does have some important dissents.

Mr. PREYER. Thank you.

The first doctors, the first scientific experts who saw the President after he was shot, were the doctors at Parkland Hospital who operated on him.

Those doctors actually saw the bullet wound in the President's throat and they described it as an entry wound, while you have described it as an exit wound. Can you explain why that's the case?

Dr. BADEN. Yes, sir. It is not uncommon for medical examiners in the course of their investigations of persons who have been injured and treated at hospitals to arrive at different opinions than the treating physician's as to the identification of entrance and exit gunshot wounds.

The reasons for this is that surgeons who treat live patients are most concerned and have greatest expertise in treating the injury suffered by the patient and are little concerned and little trained in distinguishing some of the fine points of differences between entrance and exit gunshot wounds, because this does not have much pertinence to treatment and therapy.

I think, in this particular incident, the exit perforation in the throat was small and did have some characteristics of an exit wound because of its smallness and roundness which may have been, in part, due to the fact that it came out right beneath the collar and tie of the President where the skin was held fairly firm.

An exit perforation through firm skin is smaller than through lax skin.

And in addition, the physicians who treated the President at Parkland Hospital did not turn the President over so they did not know there was another bullet hole in the back. There is a natural tendency, when a doctor sees one bullet hole and not a second bullet hole, to just assume that the one he sees is an entrance wound.

The treatment of the President, the outcome, would not have been any different had different perceptions been made by the doctors. Clearly, despite early confusion as to whether the bullet wound in the neck was an entrance or an exit perforation, the panel members all unanimously agree that it is indeed an exit perforation.

Mr. PREYER. You mentioned another fact about the Parkland Hospital examination, which has been puzzling to many of us and that is why the doctors did not report the wound in the President's back. I gather you were saying they were primarily concerned with the medical treatment of the President and simply did not turn him over?

Dr. BADEN. Yes, sir, they responded, and properly so, by trying to establish breathing by inserting an air tube and by trying to get the heart to start functioning. All these procedures are done, performed, with the patient on his back and they never had the time or opportunity to turn the President over. They just did not know that there was an entrance wound in the upper back.

Of course, this error was compounded by the autopsy physicians who, when they started the autopsy, did not appreciate that the tracheostomy wound, the incision made to insert an airway, was made through the exit perforation.

So, there were two sets of confusions that compounded the problem.

Mr. PREYER. After the President's body was brought back to Washington, the official autopsy was performed out at Bethesda. The pathologists who did the autopsy actually saw the President's body, of course. Your panel has placed the head wound some 4 inches higher than those physicians placed it. How do you account for that when those physicians actually saw the President's body and your panel did not?

Dr. BADEN. Yes. I think, in general, the doctors who perform the autopsy have a better opportunity to make valid observations than those who come later, but in this instance, the photographs taken during the course of the autopsy and the X-rays taken during the course of the autopsy and the autopsy report itself provide sufficient evidence for the panel members to arrive at valid, we feel, valid, independent conclusions.

Further, we had opportunity to interview and we did extensively interview the physicians who did the autopsy, Dr. Humes, Dr. Boswell, and Colonel Finck.

In all candor, these three pathologists, to the present time, do feel that the entrance perforation is 4 inches lower than we have concluded. They place the entrance perforation approximately in the area of that dried brain tissue in the lower portion of the scalp above the hairline.

We disagree with these doctors and we do agree with the observations of the doctors in the Clark panel and the Rockefeller Commission who also independently agreed it was 4 inches higher than the autopsy doctors stated. Our conclusion, in part, is that the observations that these three pathologists made were valid in describing the wound and the characteristics of the wound, but in making the report up the next day, not in the presence of the body, the location of the entrance perforation in the back of the head was mistakenly placed 4 inches lower than it actually was.

Mr. PREYER. So that the original autopsy panel maintained, and I gather still maintains, that what you have described as brain tissue was actually the entry wound in the head? What did they say about the entry wound that you described as being 4 inches higher?

Dr. BADEN. In discussions with the three doctors and looking together at the same photographs, the doctors who did the autopsy feel that what we identify as an entry wound is an artifact, perhaps dried blood, and not a perforation. I think that the committee will have opportunity to hear testimony from Dr. Humes, who did perform the autopsy, later today, and he can give you his reasoning. We, as the panel members, do feel after close examination of the negatives and photographs under magnification of that higher perforation, that it is unquestionably a perforation of entrance; and we feel very strongly, and this is unanimous, all nine members, that X-rays clearly show the entrance perforation in the skull to be immediately beneath this perforation in the upper scalp skin; and further, although the original examination of the brain was not complete, photographs of the brain were examined by the panel members, and do show the injury to the brain itself is on the top portion of the brain. The bottom portion or undersurface of the brain, which would have had to have been injured if the bullet perforated in the lower area as indicated in the autopsy report, was intact. If a bullet entered in this lower area, the cerebellum portion of the brain would have had to be injured and it was not injured.

So that is the basis for what remains a disagreement between our panel and the original autopsy doctors.

Mr. PREYER. Is it at all possible, Doctor, that there could have been two entry wounds, the one described by your panel in the higher part of the head, and the one described by the original autopsy panel, 4 inches lower?

Dr. BADEN. I think we physicians learn that when a question is asked, "is it possible," that many things are possible. It is the firm conclusion of the panel members, however, that, beyond all reasonable medical certainty, there is no bullet perforation of entrance any place on the skull other than the single one in the cowlick area.

It is the firm conclusion of the panel that there is no bullet perforation of entrance beneath that brain tissue nor any place else on the skull and we find no evidence to support any but a single gunshot wound of entrance in the back of the President's head.

Mr. PREYER. Turning to another question that has come up concerning the single bullet theory, you mentioned Dr. Shaw, who operated on Governor Connally. Isn't it true that Dr. Shaw testified

before the Warren Commission that he did not believe the single bullet theory, and if so, how do you account for it?

Dr. BADEN. Yes, Mr. Preyer, he did so testify before the Warren Commission. In fact, I had occasion to speak with Dr. Shaw recently and to determine the basis for his disagreement.

And he advised me that he still feels that the single bullet theory is untenable. But the basis for this belief essentially is what was told to him by Governor Connally and Mrs. Connally at the time he treated the Governor in Parkland Hospital; his basis is what they heard, what they observed, what they perceived.

He feels that Governor and Mrs. Connally are good witnesses, have good memory of what happened and in relying on the information that they gave to him, he concludes that one bullet did not pass through the President and through the Governor.

He does not make that determination on the basis of the medical, surgical, or pathological findings. In discussing the matter with him, he indicates that what he saw at surgery is consistent with a single bullet; but in taking other material into account, especially the Governor's recollection of what happened, and Mrs. Connally's recollection, he feels that for these other reasons, not the medical ones, the single bullet theory is not tenable.

Mr. PREYER. So, his opinion is based partly, at least, on eyewitness testimony rather than purely scientific?

Dr. BADEN. On persuasive eyewitness testimony, yes, sir.

Chairman STOKES. Will the gentleman suspend? Those are the second bells, There is an extremely important vote on the floor of the House, and I think this would perhaps be an appropriate time for us to suspend.

The Chair will recess the hearings until 1:30 this afternoon, at which time Mr. Preyer will resume questioning of the witness.

We are now recessed.

[Whereupon, at 11:45 a.m., the committee recessed, to reconvene at 1:30 p.m. the same day.]

AFTERNOON SESSION

Chairman STOKES. At this time, the committee will come back to order.

The Chair recognizes the gentleman from North Carolina, Mr. Preyer.

Mr. PREYER. Thank you, Mr. Chairman.

Dr. Baden, I would like to go back to an earlier question and see if we can't clear it up a little more. That is the difference between the autopsy panels, the original autopsy panel's finding of the entrance of the head wound and your panel's findings.

Your panel's findings put it some 4 inches above the entry found by the original autopsy panel. I believe you have testified that there was no possibility in your judgment, at least you were strongly convinced there were not two wounds.

I would like to ask the clerk if she could put on the easel JFK exhibit F-53. This is the enhanced computerized photograph of the President's skull, a technique which I assume was not available to the original autopsy panel.