

Mr. PURDY. Thank you, Mr. Chairman.  
Gentlemen, I will begin the questioning with Dr. Levine.

**TESTIMONY OF DR. LOWELL LEVINE, CONSULTANT TO THE  
CHIEF MEDICAL EXAMINER, NEW YORK CITY, AND CALVIN  
S. McCAMY, CHAIRMAN OF THE AMERICAN NATIONAL  
STANDARDS WORKING GROUP ON PRINT QUALITY FOR OPTI-  
CAL CHARACTER RECOGNITION**

Mr. PURDY. Mr. McCamy, if you have any comments during the questions directed to Dr. Levine, please feel free to add them.

Dr. Levine, what is your occupation?

Dr. LEVINE. I am a dentist.

Mr. PURDY. How does the process of dental identification work?

Dr. LEVINE. The forensic odontologist or forensic dentist will examine a particular piece of dental evidence and attempt to find all the particular unique and individual characteristics in that piece of evidence. He will then attempt to secure a prior record which contains those same characteristics.

Mr. PURDY. In the case of the X-rays of President Kennedy, what was your task?

Dr. LEVINE. My task basically was to examine the films taken during the course of the autopsy of President Kennedy and to determine if in fact the person who was X-ray was the late President.

Mr. PURDY. To what extent are X-rays considered adequate for identification purposes?

Dr. LEVINE. X-rays are excellent dental evidence for identification purposes. They contain the positions of the teeth in relation to each other. They contain the shapes and sizes of the fillings and the lining or basing materials that the teeth contain. We can find anomalous or bizarre situations, pathology such as cysts, roots, and consequently there are a myriad of areas for comparison in X-ray film.

Mr. PURDY. Do X-rays exist showing the teeth and jaws of President Kennedy taken prior to the autopsy X-ray?

Dr. LEVINE. Yes sir, they do.

Mr. PURDY. Where are they?

Dr. LEVINE. There were 22 such films in the custody of the National Archives.

Mr. PURDY. Generally, what do these films show?

Dr. LEVINE. Thirteen of the films are dental X-ray type films. The other nine are marked JFK sinus. The X-ray films show teeth, jaws, dental restorations, bony patterns, and the like. The sinus films are both anterior, posterior, front to back, and lateral skull films taken side to side.

Mr. PURDY. What is the basis for your opinion as to whether or not the autopsy X-rays were actually made on President Kennedy?

Dr. LEVINE. Well, the first thing that I did was to compare each of the photographs in the National Archives with each other and I was very readily able to determine that all the films were taken on the same person, President Kennedy. There are four sources of the films, including a Captain Petter of the U.S. Navy Dental Corps, and a Dr. Robert Morris of New York City.

The sinus films were taken by Dr. Stephen White of New York City, and by Drs. Groover, Christie, and Merit in Washington, D.C., through the years 1960 to 1962. These names appear either on the films themselves or on the film mounts, which is normal procedure.

Mr. PURDY. Dr. Levine, will you please examine these items marked JFK exhibits F-295 and F-296 and tell us what they represent?

Dr. LEVINE. May I walk over there, Mr. Counsel?

Mr. PURDY. Yes.

Dr. LEVINE. F-295 is a composite of certain of the films in the National Archives, and autopsy films 1 and 2. I have in fact examined autopsy films 1, 2, and 3 and was able to authenticate all of those, but at the time I had my permission to do the photography work it was my understanding that I was not to photograph injury pattern and in order to authenticate film No. 1 that would have showed injury pattern in that the frontal sinuses were used to authenticate autopsy film 1.

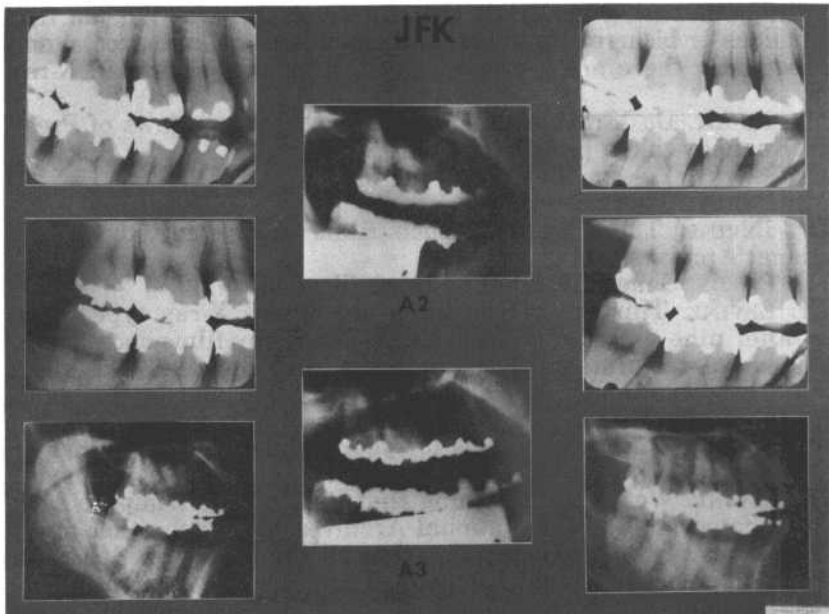
Mr. PURDY. Dr. Levine, what do the autopsy Nos. 1, 2, and 3 represent, what views of the President?

Dr. LEVINE. They are all skull films. Autopsy 1 is a front to back and back to front—an AP-type film. Nos. 2 and 3 represent lateral films taken from side to side, so to speak.

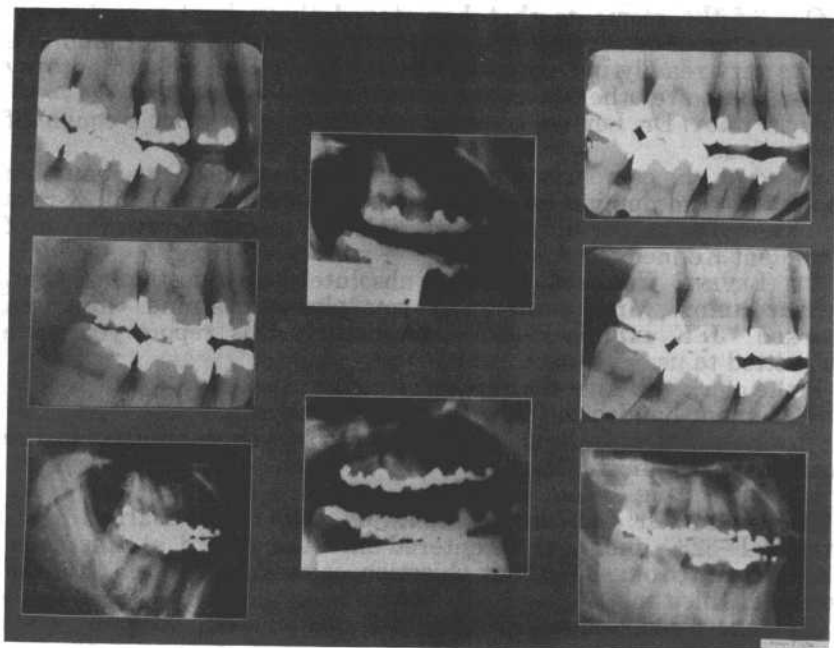
Mr. PURDY. Mr. Chairman, I would like to have these exhibits, marked JFK F-295 and F-296, introduced into the record at this time.

Chairman STOKES. Without objection, they may be entered into the record at this time.

[The above-referred-to JFK exhibits F-295 and F-296 follow:]



JFK EXHIBIT F-295



JFK EXHIBIT F-296

Mr. PURDY. Could you please demonstrate the areas of comparison in the exhibits?

Dr. LEVINE. Yes, sir. The four films on top in F-295—and these in F-296—are actually duplicates of each other with certain of the areas of comparison color coded in red. The four films on top were taken by Dr. Robert Morris in New York City I believe on January 18, 1962, right side and left side. The film in the lower corner on both the exhibits on the “J” side is the Stephen White film taken on August 14 of 1960, and the film on the left side is the Drs. Groover, Christy, and Meritt film taken in Washington, D.C., and this is of a lateral skull film on August 17, 1960.

This is the dentition and supporting structures on both autopsy 2 and autopsy 3. We can see some very distinctive areas that makes comparison not too difficult. But one thing we must understand, the dental films are taken by placing the piece of film in the mouth, and so you get the one tooth.

The lateral skull films are taken by passing the X-rays, so to speak, through the skull to the film on the other side, so that we get a composite very often, or the teeth of both sides superimposed upon each other, which has happened in the four films here. We have elements then of both the right and left sides in autopsy 2 and autopsy 3.

Autopsy 3 is very evident from the very distinctive shapes of the fillings. For example, in the upper second molar we see a “W” shape filling and we can follow them as we go forward. So that there is absolutely no difficulty in authenticating that.

One of the elements that has stayed throughout is a kidney-shaped area of cement base in the lower left second molar, and this shows very readily in this area here, in the 60 film, in both autopsy films. There are others, too, just to point out—

Mr. PURDY. Dr. Levine, I appreciate your pointing out a couple of those areas.

Based on the comparison X-rays that you have used, are you able to state a firm opinion as to whether or not the three skull X-rays you viewed from the autopsy materials are in fact X-rays taken of President Kennedy?

Dr. LEVINE. Yes, sir, there is absolutely no question of that.

Mr. PURDY. Mr. Levine, will you please examine this item marked "JFK exhibit F-323" and identify this report you have submitted to us.

If the clerk will give the report.

[Document handed to the witness by the clerk.]

Mr. PURDY. Dr. Levine, is this the report you submitted to the staff of this committee?

Dr. LEVINE. Yes, it is.

Mr. PURDY. Mr. Chairman, I would like this report marked "JFK exhibit F-323" and have it entered into the record at this time.

Chairman STOKES. Without objection, it may be entered into the record at this time.

[The above-referred-to JFK exhibit F-323 follows:]

JFK EXHIBIT F-323

REPORT TO THE  
SELECT COMMITTEE ON ASSASSINATIONS  
U. S. HOUSE OF REPRESENTATIVES

Identification of the Skull X-Ray  
Films Taken During the Autopsy of  
President John F. Kennedy

Lowell J. Levine, D.D.S.  
Consultant for the  
Select Committee on Assassinations  
U. S. House of Representatives  
September 7, 1978

AUTHENTICATION OF AUTOPSY FILMS 1, 2, 3 ( BY DR. LOWELL LEVINE)

BASIS FOR DENTAL IDENTIFICATION

The science of dental identification is based upon the fact that characteristics associated with the dentition and the hard and soft tissue structures of the oral cavity occur in astronomical numbers of combinations.

Typically, the adult dentition contains sixteen teeth in each jaw; four incisors, two canines, four premolars, and six molars. Each tooth has characteristics such as morphology, root configuration, root canal shapes, anomalies, pathology, and the like which are unique and individual to that particular tooth. Similarly, the supporting structures of the oral cavity have unique and individual characteristics.

Teeth are often attacked by carious lesions (decay) and other processes which cause unique and individual characteristics.

There are five surfaces on each tooth which may be attacked by dental caries and restored by the dentist. On posterior teeth ( premolars and molars ), mesial and distal ( towards and away from the midline ), occlusal ( the grinding surface ), buccal ( towards the cheek ), and lingual ( towards the tongue ). On anterior teeth ( incisors and canines ) mesial and distal, facial or labial ( towards the face or lips ), lingual, and incisal ( cutting surface ). These surfaces may be attacked by dental caries singly or in combination and restored by the

dentist in single or multiple surface restorations. Different surfaces on the same tooth may be restored with various filling, insulating, and lining materials. Different sized and shaped dental burs ( drills ) are used to remove the dental caries, and prepare the tooth to receive the filling material.

The dentist uses various materials to repair the effects of dental caries. Metals such as gold in various forms and silver amalgam are commonly used. Porcelains and acrylics are used and various cements are used as temporary restorations, insulating materials, and sealers.

It should be abundantly clear that the possible combinations which may occur because of such factors as presence or absence of particular teeth, surfaces of each tooth free of caries or decayed, surfaces of each tooth present restored with various types of dental materials, sizes and shapes of cavity preparations is limitless.

Almost all dental evidence is useful for identification purposes. Dental evidence could include the written records of examinations and treatments, Models of the mouth, teeth, and jaws used for diagnosis and treatment planning or the actual fabrication of prosthetic appliances. The prosthetic appliances themselves. Photographs and x-ray films taken incident to diagnosis and/or treatment.

X-ray films are excellent evidence for identification purposes. The films will graphically exhibit characteristics such as presence or absence of teeth, rotations of teeth, level of eruption of teeth, tipping of teeth, and the relation of these teeth to each other.

The films will show the morphology of teeth, roots, and root canals as well as the presence of caries, root canal therapy, pathology such as retained roots and cysts, unerupted teeth, anomalies, wear, and breakage among other things.

We may examine the shapes of fillings, extent of caries involvement and removal, cement materials present, and density of filling materials. Hard tissue patterns, pathology, and landmarks are also graphically represented.

Even when extensive dental treatment, performed subsequent to the date of the x-ray films, has considerably altered the visual appearance of the teeth, the underlying hard tissue characteristics remain quite distinctive.

#### DENTAL IDENTIFICATION PROCESS

The dental identification process will include a comparison by the forensic odontologist of the unique and individual characteristics exhibited by the evidence at hand with previously existing records containing evidence of those same characteristics. The forensic odontologist will use his training, experience, skill, and expertise to form an



an opinion as to whether his comparison is positive. He will render that opinion in a report which will also contain the basis for that opinion.

The early use of dental identification in the United States can be documented in two historically significant cases which both occurred in President Kennedy's home state of Massachusetts.

Paul Revere, noted for his famous ride and as a silversmith, also practiced dentistry. General Joseph Warren, a Revolutionary War hero killed at the Battle of Bunker Hill, had been a patient of Revere. Originally buried by the British, his remains were subsequently identified by Revere some ten months later when Revere recognized a prosthetic appliance he had made for General Warren.

In 1850 the Webster-Parkman case shocked Boston. Dr. John White Webster, Professor of Chemistry and Mineralogy at Harvard Medical School was convicted of murdering Dr. George Parkman, Professor of Anatomy at Harvard Medical School. In this first recorded instance of dental identification in the courtroom, Dr. Nathan Cooley Keep, subsequently first Dean of Harvard Dental School, identified a few fragments of lower jaw and an intact porcelain bridge which fitted the cast Dr. Keep had preserved from recent dental care of the missing Dr. Parkman. An expert witness for the defense was William Morton, the young Boston dentist of ether anesthesia fame.

---

Historical References:

Sognaes, Reider F., "Talking Teeth", American Scientist, Vol.64,p.369  
Luntz & Luntz, Handbook for Dental Identification, J.B. Lippincott,  
Phila., 1973, pp. 1-15

EVIDENCE USED IN THE DENTAL IDENTIFICATION PROCESS

The evidence to be used for the comparisons was in the custody of the National Archives of the United States at the time I examined it. There was a "Descriptive List" of the materials which was apparently made when the National Archives received them from the Kennedy Library.

"Descriptive List" ( Items I personally used for comparisons )

1. Manila Envelope - Business Letter Size  
Addressed to Captain J.W. Pepper, D.C., USN  
containing two dental films, loose  
JFK 7/12/62
2. Manila Envelope - Business Letter Size  
marked JFK 4/9/62  
containing two dental films, loose
3. Manila Envelope- About 5" x 6"
  - a. one mounted dental film dated 3/11/61
  - b. two mounted dental films dated 3/11/61
  - c. five mounted dental films dated 1/18/61
  - d. one mounted dental film dated 3/8/62
6. Manila Sleeve, about 10 x 12  
JFK Sinus Films, 8-17-60  
containing five films
7. Manila envelope (sic), about 10 x 12  
JFK Sinus Films, 8-14-60  
containing four films

Description of 1, 2, 3, 6, 7: \*

1. Two dental films loose : Both are left mandibular periapical\*\* type films. The root apices (ends of the roots) do not appear on the films. One film is taken slightly anterior to the other. The anterior film includes a portion of the lower left canine, both lower left premolars, the lower left first molar, and a portion of the lower left second molar. ( Universal numbers 22, 21, 20, 19, 18 )

The posterior film includes a portion of the lower left first premolar, the lower left second premolar, the lower left first molar, and a portion of the lower left second molar. ( Universal numbers 21, 20, 19, 18 )

The following surfaces are interpreted to be restored:

First Premolar (#21) - Distal Occlusal

Second Premolar (#20) - Mesial Occlusal Distal

First Molar (#19) - Mesial Occlusal Distal

Second Molar (#18) - Mesial Occlusal

The restorations are interpreted as cast metal restorations. A less radio opaque material pulpal ( towards the "nerve" ) to the restorations is interpreted as dental cement. The lower left first molar (#19) appears to have a portion of a previous metallic restoration on the pulpal floor.

\* The teeth will be described by name and by the Universal Numbering system. In this system the Maxillary (upper) Right Third Molar is #1, The Maxillary Left Third Molar #16, the Mandibular (lower) Left Third Molar #17, the Mandibular Right Third Molar #32

\*\* This type film usually is of the crown and root portions of a tooth or teeth in a segment of one jaw.

2. Two dental films loose: Both are left mandibular periapical type films. One film includes the root apicies, the other does not. Both films include a portion of the lower left canine, the two lower left premolars, the lower left first molar, and a portion of the lower left second molar. ( Universal Numbers 22, 21, 20, 19, 18 )

The following surfaces are interpreted to be restored:

First Premolar-(#21) - Distal Occlusal

Second Premolar (#20) - Mesial Occlusal Distal

First Molar (#19) - Mesial Occlusal Distal

Second Molar (#18) - Mesial Occlusal

The restorations are interpreted as cast metal restorations. A less radio opaque material pulpal to the restorations is interpreted as dental cement. The lower left first molar (#19) appears to have a portion of a previous metallic restoration on the pulpal floor.

3 a. One mounted dental film dated 3/11/61 : A film mount marked, "Kennedy JP 3/11/61", contains a left Bite wing\* type film. It includes a portion of the upper left first premolar, lower left first premolar, Upper and lower second premolars , first and second molars. ( Universal Numbers 12, 13, 14, 15, 21, 20, 19, 18 )

---

\* This type film is usually of the crown portions of opposing teeth of a segment or an entire side.

The following surfaces are interpreted to be restored:

Upper: First Premolar (#12) - Mesial Occlusal Distal  
 Second Premolar (#13) - Mesial Occlusal Distal  
 First Molar (#14) - Mesial Occlusal Distal  
 Second Molar (#15) - Mesial Occlusal Distal  
 Lower: First Premolar (#21) - Distal Occlusal  
 Second Premolar (#20) - Mesial Occlusal Distal  
 First Molar (#19) - Mesial Occlusal Distal  
 Second Molar (#18) - Mesial Occlusal

The restorations are interpreted as cast metal on all surfaces except for those of the two upper premolars. The restored surfaces on these two teeth are metallic and may be either cast metal or silver amalgam. There is dental cement pulpally on all teeth except the upper and lower first premolars. There appears to be a portion of a previous metallic restoration on the pulpal floor of the lower left first molar.

3 b. Two mounted dental films dated 3/11/61 : A film mount marked, "Kennedy John F 11 March 61" contains two maxillary left periapical type films. These include a portion of the upper first premolar, upper second premolar, upper first molar, and upper second molar. ( Universal Numbers 12, 13, 14, 15 )

The following surfaces are interpreted to be restored:

First Premolar (12) - Distal Occlusal ( mesial portion of tooth is )  
not shown on the film  
Second Premolar (13) - Mesial Occlusal Distal  
First Molar (14) - Mesial Occlusal Distal ( probably lingual )  
Second Molar (15) - Mesial Occlusal Distal

All restorations are interpreted as being of metal with the molars probably cast metal. There is cement visible under all restorations with the exception of the first premolar.

3 c. Five mounted dental films date 1/18/61: A film mount marked, "Kennedy, Pres John F 1-18-61". The mount bears a stamp, "Robert D. Morris, D.D.S., 140 East 54th St., New York, 22, N.Y.". \* The mount contains five x-ray films. There are two right bite wing type films, two left bite wing type films, and one maxillary left periapical type film.

One right bite wing film is taken anterior to the other. The more anterior film contains a portion of the upper and a portion of the lower canine, the upper and lower first and second premolars, the upper and lower first molars, a portion of the upper and lower second molars. The more posterior film contains a portion of the upper and a portion of the lower second premolars,

---

\* Dr. Morris confirmed the fact that he treated President Kennedy on 1/18/61 in a telephone conversation which occurred on June 7, 1978. This appointment was two days prior to his inauguration. He had a routine "check up" which included x-rays and "cleaning".

the upper and lower first and second molars.

The following surfaces are interpreted to be restored:

Upper Right: Canine (6) - Distal

    First Premolar (5) - Occlusal

    Second Premolar (4) - Mesial Occlusal Distal

    First Molar (3) - Mesial Occlusal Distal

    Second Molar (2) - Mesial Occlusal

Lower Right: First Premolar (28) - Occlusal, Occlusal

    Second Premolar (29) - Distal Occlusal

    First Molar (30) - Mesial Occlusal Distal

    Second Molar (31) - Mesial Occlusal

The upper right canine is interpreted as having a cement restoration. All other restorations are metal. The first premolars appear to have silver amalgam restorations, all others appear to be cast metal. There appears to be cement pulpal to all restorations except those of the first premolars.

One left bite wing film is taken anterior to the other. Both films include the upper and lower first premolars, second premolars, first molars and second molars. The more anterior film includes a portion of the upper and lower second molars, the more posterior film, a small portion of the upper and lower first premolars.

The following surfaces are interpreted to be restored:

Upper Left: First Premolar (12) - Distal Occlusal

    Second Premolar (13) - Mesial Occlusal Distal

Upper Left: First Molar (14) - Mesial Occlusal Distal  
 Second Molar (15) - Mesial Occlusal Distal  
 Lower Left: First Premolar (21) - Distal Occlusal  
 Second Premolar (20) - Mesial Occlusal Distal  
 First Molar (19) - Mesial Occlusal Distal  
 Second Molar (18) - Mesial Occlusal

The restorations are interpreted as cast metal on all surfaces with the exception of the two upper premolars. The restored surfaces on these two teeth are metallic and may be either cast metal or silver amalgam. There is dental cement pulpally on all teeth except the upper and lower first premolars. There appears to be a portion of a previous metallic restoration on the pulpal floor of the lower first molar.

The maxillary left periapical film includes a portion of the upper first premolar, second premolar, first and second molars.

The following surfaces are interpreted to be restored:

Upper Left: First Premolar (12) - Distal Occlusal  
 Second Premolar (13) - Mesial Occlusal Distal  
 First Molar (14) - Mesial Occlusal Distal (probably lingual)  
 Second Molar (15) - Mesial Occlusal

The restored surfaces of the molars are interpreted as cast metal. The premolars may be either cast metal or silver amalgam. There appears to be cement under all restorations with the exception



of the first premolar.

3 d. One mounted dental film dated 3/8/62 : A film mount marked, " JF Kennedy 3/8/62 " contains an upper left periapical type film. The film includes a portion of the upper left canine, first and second premolars, first molar, and a portion of the second molar.

The following surfaces are interpreted to be restored:

Upper Left: First Premolar (12) - Distal Occlusal

Second Premolar (13) - Mesial Occlusal Distal

First Molar (14) - Mesial Occlusal Distal

Second Molar (15) - Mesial Occlusal (the distal portion of )  
#15 is not in the film

All surfaces are restored in metal. The molars appear to be restored with cast metal the premolars with either cast metal or silver amalgam. Cement is apparent pulpally on all teeth but the first premolar.

6. JFK Sinus Films, 8-17-60, ... five films: There is a container marked, " 5 sinus films " J.F.K.

It is labelled, " Name Kennedy, Mr. John F.

No. 336042

Remarks 8/17/60

Drs. Groover, Christie & Merritt

1835 Eye Street N.W.

Washington, 6, D.C.

The manila sleeve contains five x-ray films. One is a lateral skull film. Four are AP films taken at various angulations.

The configuration of the frontal sinuses can be clearly determined from the AP films.

The following dental restorations can be interpreted from the lateral skull film:

Upper Left: First Premolar (12) - Distal Occlusal  
 Second Premolar (13) - Mesial Occlusal Distal  
 First Molar (14) - Mesial Occlusal Distal  
 Second Molar (15) - Mesial Occlusal Distal  
 Lower Left: First Molar (19) - Mesial Occlusal Distal  
 Second Molar (18) - Mesial Occlusal

Superimposition in the premolar area makes clear interpretation difficult. Overlapping makes clear interpretation difficult towards the anterior region.

These restorations all appear to be metallic. Cement can be clearly seen pulpal to the restorations in the molar area. The appears to be a portion of a previous metallic restoration pulpal to the restoration and cement liner on the lower left first molar (19).

7. JFK Sinus Films, 8-14-60...4 films : There is a container marked, " #202617

8-14-60

JFK

Dr. Stephen White

'Sinus X-Rays'

The envelope contains one lateral skull film  
and three AP type films taken at various angulations.

The configuration of the frontal sinus can be clearly determined from the AP films.

The following dental restorations can be interpreted from the lateral skull film:

Upper Right second molar (2) - Occlusal portion of restoration  
Upper Left Second Molar (15) - Distal portion of restoration  
Lower Right First Molar (30) - Mesial Occlusal Distal  
Lower Right Second Molar (31) - Mesial Occlusal

There is considerable superimposition and overlap.

Authenticity of 1., 2., 3 a., 3 b., 3 c., 3 d., 6., 7.

The first task of the forensic odontologist is to form an opinion as to whether the films he will use for comparison with the films in question are authentic. The twenty-two films described were received by the National Archives from the Kennedy Library. According to a source at the Kennedy Library, the films were found in the White House after the death of the President. They came to the Kennedy Library through a family member.\*

Dates of Films and Source:

8/14/60 - Lateral Skull Film - Dr. Stephen White, #7  
Three AP skull films  
8/17/60 - Lateral Skull Film - Drs. Groover, Christie & Merritt  
Four AP Skull Films #6

---

\* William Moss, Chief Archivist, Kennedy Library

- 1/18/61 - five dental films - Dr. Robert D. Morris - #3 c.  
 two right bite wings  
 two left bite wings  
 one left maxillary periapical
- 3/11/61 - three dental films - Captain J.W. Pepper, D.C., USN - #3 a., 3  
 one left bite wing  
 two left maxillary periapical s
- 3/8/62 - one dental film - Captain J.W. Pepper, D.C., USN - #3 d.  
 one left maxillary periapical
- 4/9/62 - two dental films - Captain J.W. Pepper, D.C., USN - #2  
 two left mandibular periapicals
- 7/12/62 - two dental films - Captain J.W. Pepper, D.C., USN - #1  
 two left mandibular periapicals

Films of the Left Side:

- #1 - 2 films 7/12/62 - two mandibular periapicals  
 #2 - 2 films 4/9/62 - two mandibular periapicals  
 #3a- 1 film 3/11/61 - bite wing  
 #3b- 2 films 3/11/61 - two maxillary periapical  
 #3c- 3 films 1/18/61 - two bite wings, one maxillary periapical  
 #3d- 1 film 3/8/62 - maxillary periapical  
 #6 - 1 film 8/17/60 - lateral skull

There are twelve films taken over a twenty-three month period by at least three different sources, Drs. Pepper, Morris, and White.

Films of the Right Side:

#3c - 2 films 1/18/61 - two bite wings

#7 - 1 film 8/14/60 - lateral skull (also shows portion of left)

There are three films taken in a five month period by two different sources, Dr. Morris and Drs. Groover, Christie & Merritt.

There are seven films useful for comparing frontal sinus configurations, # 6 and #7 from two different sources, Dr. White and Drs. Groover, Christie & Merritt. \*

Opinion as to the authenticity of the films to be used for comparisons

Dr. Robert D. Morris confirms the fact that he did expose x-ray films on President John F. Kennedy on January 18, 1961. There are numerous unique and individual characteristics reproduced in the fifteen films illustrating the dentition. The films were acquired from at least four different sources. Films taken in like areas may be easily compared with each other. It is my opinion that all films were taken on the same person, John F. Kennedy.

---

\* It is interesting to note that President Kennedy had numerous x-ray films of the left side taken in the period between 3/11/61 and 7/12/62. One could speculate that he was suffering from some non-specific dental pain of the left posterior area during that period.

Autopsy Films 1, 2, 3

## Description of Films:

1. AP Skull Film
2. Lateral Skull Film
3. Lateral Skull Film

Each film is marked, " 21296"

U.S. Naval Hospital

NNMC, Bethesda, Md.

Description of areas of comparison of Autopsy 1, 2, 3

Autopsy 1. The configuration of the frontal sinuses are quite distinctive. The right side is "heart" shaped, the left almost "rhomboid".

Autopsy 2. There is considerable superimposition and overlap of the jaws, teeth, and restorations, however the right side appears slightly superior. There is a <sup>radio opaque</sup> rectangular shaped object with ~~the~~ small and one large radiolucent circular areas in it extending from the second lower premolar considerably beyond the third molar area. It obliterates the roots of ~~the~~ molars and extends at an angle beyond the inferior border of the mandible. Because of the angulation at which this film was taken, this object is parallelogram shaped, the circular areas oval shaped.

The configuration and juxtapositions of a number of the dental restorations are useful for comparison purposes. The two occlusal restorations can be clearly interpreted on the lower right first premolar (28) as can the occlusal portion of the distal occlusal restoration on the lower right second premolar (29). In the second molar area the two second molars are superimposed upon each other. The very distinctively shaped cement liner in the lower left second molar (18) is quite apparent. It is kidney shaped with the concavity towards the pulpal floor. The deeper portion extends towards the distal. Immediately above the cement liner is the occlusal portion of the mesial occlusal restoration. The concave distal occlusal wall is apparent. The shallow portion of the distal occlusal wall of the mesial occlusal restoration in the lower right second molar (31) can be interpreted immediately above the convexity of the distal occlusal wall of the lower left second molar (18) restoration. The deeply rounded floor of the mesial portion of the mesial occlusal restoration on the lower left second molar (18) can be seen.

The distal portions of restorations on the upper second molars can be interpreted although considerably superimposed upon each other.

There are unquestionably ample unique and individual characteristics which can be interpreted for comparison purposes. contained in this film.

Autopsy 3. There is no superimposition of the maxillary left segment. Although there is slight overlap, the configuration and juxtapositions of the dental restorations in this segment can be readily interpreted. There is superimposition of the right maxillary molar area on the superior portion of the occlusal of the lower right second premolar(29) and lower right first molar(30). There is a radio opaque rectangular object, apparently the same object as in Autopsy 2., which obliterates almost entirely both lower left premolars, the roots of the lower left first molar, and a portion of the roots of the lower left second molar. The lower left second molar appears free of distortions.

The characteristics of the restorations and existing lining materials can be readily interpreted on the following

teeth: Upper Left: First premolar (12)

Second premolar (13)

First molar (14)

Second molar (15)

Upper Right: First premolar(5)

Second premolar(4)

Lower Left: First molar(19)

Second molar(18)

There are numerous unique and individual characteristics which can be interpreted for comparison purposes contained in this film.



Comparisons

Autopsy 1. The configurations and relationships of the frontal sinuses depicted in this film and in films contained in Sinus 6. and Sinus 7. are similar.

Autopsy 2. The unique and individual characteristics described in this film can also be interpreted in films contained in:

1., 2., 3a., 3c., 6., 7

Autopsy 3. The unique and individual characteristics described in this film can also be interpreted in films contained in:

1., 2., 3a., 3b., 3c., 3d., 6., 7.

Conclusions

It is my opinion that Autopsy Films 1., 2., 3. are unquestionably of the skull of President John F. Kennedy. It is further my opinion that the unique and individual dental and hard tissue characteristics which may be interpreted from Autopsy Films 1., 2., 3. could not be simulated.

*Lowell J. Levine D.D.S.*

Lowell J. Levine, D.D.S.

Exhibits

Comparison of dental x-rays are visually quite persuasive when presented to juries of lay persons as photographic "blow-ups". The forensic odontologist can easily demonstrate the characteristics and relationships he has interpreted to form his opinion.

Almost at the outset of my examination in consultations between Dr. Michael M. Baden, the committee staff, and myself, it was decided it would be very desirable to attempt to get permission to reproduce portions of x-ray films which were significant in forming my opinion.

The strongest reason for publishing facsimiles of the x-ray evidence is that they are so much more convincing than a narrative description of characteristics compared.

The committee staff obtained permission for me to photograph and reproduce portions of the films I felt were necessary to document the identification and authentication. Autopsy 1. was not photographed at that time because it was my understanding that my permission precluded reproducing areas which depicted injury pattern. The fact that documentation of Autopsy 1. is not included in these exhibits should in no way be construed to imply that my opinion as to the authenticity of that film is less than a positive identification, anything/.

On November <sup>15, 1977</sup> I personally photographed the films at the National Archives. The exhibits were produced under my direction by Walter Poppe, Forensic Photographer, Office of the Medical

Examiner, Nassau County, N.Y. while employed as a private consultant.

Exhibits

FIG. 1 - Dental Film (Descriptive List 1.) taken 7/12/62. The more posterior of the two films described.

FIG. 2 - Dental Film (Descriptive List 2.) taken 4/9/62. One of the two films described.

FIG. 3 - Dental Film (Descriptive List 3a.) taken 3/11/61.

FIG. 4 - Dental Films (Descriptive List 3b.) taken 3/11/61.

FIG. 5 - Dental Films (Descriptive List 3c.) taken 1/18/61. Four of the five films described.

FIG. 6 - Dental Film (Descriptive List 3d.) taken 3/8/62.

FIG. 7 - Sinus Film (Descriptive List 6.) taken 8/17/60. Dentition and supporting structures depicted in Lateral Skull Film.

FIG. 8 - Sinus Film ( Descriptive List 6 ) taken 8/17/60. "Waters Position" type film.

FIG. 9 - Sinus Film ( Descriptive List 7 ) taken 8/14/60.  
Dentition and supporting structures depicted in Lateral Skull Film.

FIG. 10 - Autopsy 2. Dentition and supporting structures.

FIG. 11 - Autopsy 3. Dentition and supporting structures.

Mr. PURDY. I have no further questions for Dr. Levine. I will move on to Mr. McCamy.

What is your occupation?

Mr. McCAMY. I am a scientist specializing in photography and the measurement of color.

Mr. PURDY. Have you examined the photographs said to be taken of President Kennedy at the time of the autopsy?

Mr. McCAMY. Yes, I have.

Mr. PURDY. Did anyone else on the photographic panel examine these materials?

Mr. McCAMY. Yes; they were examined in great detail by Frank Scott, by David Eisendrath, by Bennett Sherman, and by one of the professors from RIT.

Mr. PURDY. Did you observe anything of interest in the photographs which is relevant to the issue of the authenticity of the autopsy photographs?

Mr. McCAMY. Yes; there were numbers embossed on the edges of the color films. These numbers indicate the batch numbers of emulsions. Sometimes but not always, a manufacturer of the film can date the film knowing these numbers. David Eisendrath copied down two of these numbers from the color film and he prepared a letter to the manufacturer, Eastman Kodak, asking about the date of the films. As it happened, he had some old boxes of film on which the dates were known. He took the numbers of some of those films and submitted them at the same time just as a control procedure.

Mr. PURDY. Did you notice anything else on the autopsy photographs relevant to the issue of authenticity?

Mr. McCAMY. Might I remark that the Eastman Kodak Co. did respond. They were able to date David Eisendrath's films and they were able to date the films that were taken at the time of the autopsy and they said the films were manufactured in 1963, which is an appropriate finding.

Mr. PURDY. Thank you.

As I was saying, Mr. McCamy, is there anything else you observed on the autopsy photographs relevant to the issue of authenticity?

Mr. McCAMY. Yes. Of course we examined the films in great detail to see whether or not there were any indications, any evidence whatsoever, of falsification of the photographs. We found no

disturbing of the surface of the film. We found nothing taken away from the film or added to the film, no evidence of any cutting or pasting or construction of a montage, in short, found no evidence whatsoever of any such faking.

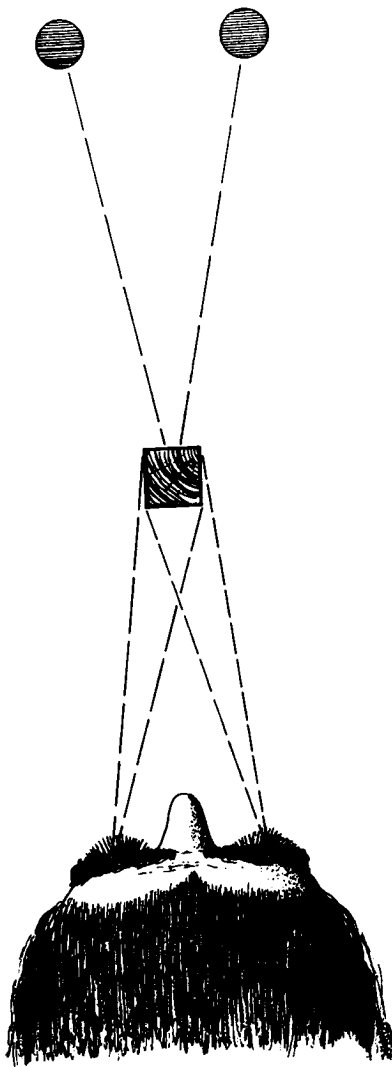
Mr. PURDY. You mentioned earlier to members of the staff that you were able to view some of the photographs stereoscopically. Could you briefly state what it means to view photographs stereoscopically and why you believe this is evidence of authenticity?

Mr. McCAMY. Yes. We have an exhibit. The human eyes are located a short distance apart.

Mr. PURDY. Mr. Chairman, could we examine this item and mark it as JFK exhibit F-294 and enter it into the record at this time.

Chairman STOKES. Without objection, it may be entered into the record at this time.

[The above referred to JFK exhibit F-294 was marked erroneously and should have been marked JFK exhibit F-203.]



JFK Exhibit F-203

Mr. McCAMY. As you can see on the diagram, if a person looks at a small square peg in front of him, the right eye may see the front and part of the side of the peg. The left eye can see the front and part of the left side of the peg. This is a disparity, a difference in the two views that the two eyes see.

Another fact is observed. For the right eye, the peg lines up with the left hand spot in that diagram in the background where, for the left eye, the peg lines up with the right hand spot, so we have what is called parallax, that is, a difference of alignment in the photograph.

Mr. PURDY. Mr. McCamy, were there autopsy photographs in which you were able to observe parallax?

Mr. McCAMY. Yes, sir.

Mr. PURDY. Which autopsy photographs were those?

Mr. McCAMY. They were photographs of the back of the head, of the top of the head, the front of the body showing the neck wound, the back showing the back wound.

Mr. PURDY. Mr. McCamy, based on your viewing of these photographs and your determination that parallax was evident in them, to what extent are you able to say that these photographs were unaltered?

Mr. McCAMY. I would say on the basis of the examination of these photographs, stereoscopically, it is highly unlikely that they were altered in any way.

Mr. PURDY. Why do you have this opinion based on viewing them stereoscopically?

Mr. McCAMY. Let me take four cases because—

Mr. PURDY. Mr. McCamy, if we could deal with the general principle of stereoscopic vision, could you tell us why your ability to view them stereoscopically permits you to say they are authentic.

Mr. McCAMY. Yes. Suppose, first, we take the possibility that someone substituted a body and that it was not the body of the President. Viewing these photographs stereoscopically provides the best kind of view because you can observe not only lateral dimensions but dimensions in depth, so it provides the best kind of view for identification.

In this case, we must remember we are looking at professional photographs taken at short range, not distant photographs, so there is very little difficulty in identifying the person and the things seen.

The fact that it is in stereo gives the observer full advantage of the information available to him.

Mr. PURDY. Mr. McCamy, then it is your opinion that based on your examination of these stereo pairs that you are able to conclude that it is very unlikely these photographs are altered?

Mr. McCAMY. Yes, extremely unlikely. We have considered the possibilities of various photographic techniques that could have been used in a train of events to produce these photographs. Some of them are virtually impossible because of the stereoviewing. Others would be exceedingly difficult, if not impossible.

Mr. PURDY. Thank you, Mr. McCamy.

Mr. Chairman, I have no further questions.

Chairman STOKES. Thank you, Counsel.

Dr. Levine, Mr. McCamy, thank you both for your testimony here this morning and you are now excused.

[Witnesses excused.]

The Chair recognizes Professor Blakey.

Mr. BLAKEY. Mr. Chairman, of those doctors involved in either the original autopsy or subsequent reviews of it, the committee has available to it today or tomorrow Dr. Baden, Captain Humes, Dr. Wecht, and Dr. Petty. Dr. Baden received an M.D. degree from New York University School of Medicine in 1959 and completed his residency in pathology at Bellevue Hospital in 1964. He is, of

course, the chairman of the committee's panel reviewing the autopsy. It would be appropriate now, Mr. Chairman, to call Dr. Baden.

Chairman STOKES. The committee calls Dr. Baden.

Dr. Baden, would you raise your right hand, please?

Do you solemnly swear the testimony you will give before this committee is the truth, the whole truth, and nothing but the truth, so help you God?

Dr. BADEN. I do.

Chairman STOKES. Thank you. You may be seated.

Before I recognize counsel. Dr. Baden, I understand you will be giving testimony relative to illustrated photographs.

**TESTIMONY OF DR. MICHAEL BADEN, PATHOLOGIST AND  
CHIEF MEDICAL EXAMINER FOR THE CITY OF NEW YORK**

Dr. BADEN. Taken at the autopsy, yes, sir.

Chairman STOKES. I guess it is important at this point that the record reflect the fact that the photographs which are sealed in the National Archives have been made available to the appropriate members of this committee staff and to the members of this committee.

The committee has viewed those photographs as late as this past evening. The committee feels it would be in extremely poor taste for this committee to submit those photographs to public view. It also, in our opinion, would be an invasion of the privacy of the President's family. It is for that reason that these photographs will remain sealed and will not be displayed during the course of these hearings.

The committee, at this time, will recognize counsel Kenneth Klein.

Mr. KLEIN. Thank you, Mr. Chairman.

Doctor, what is your current position?

Dr. BADEN. I am Chief Medical Examiner of the City of New York.

Mr. KLEIN. What are your duties as chief medical examiner of the city of New York?

Dr. BADEN. My duties include supervision and responsibility for the functioning of the Office of Chief Medical Examiner of New York City, which has responsibility to investigate all sudden, suspicious, and unnatural deaths that occur in the five boroughs of New York City.

Mr. KLEIN. During the course of your duties as Chief Medical Examiner, do you perform autopsies?

Dr. BADEN. Yes, sir.

Mr. KLEIN. What is an autopsy?

Dr. BADEN. An autopsy is a systematic external and internal examination of the dead body to determine any abnormalities that might be present to assist in determining cause of death.

Mr. KLEIN. What is your specialty as a medical doctor?

Dr. BADEN. My specialty is pathology and within that area, forensic pathology.

Mr. KLEIN. What is forensic pathology?

Dr. BADEN. Pathology is that area of medicine concerned with the investigation and evaluation of natural disease and other abnormalities in the human body; and forensic pathology specifically