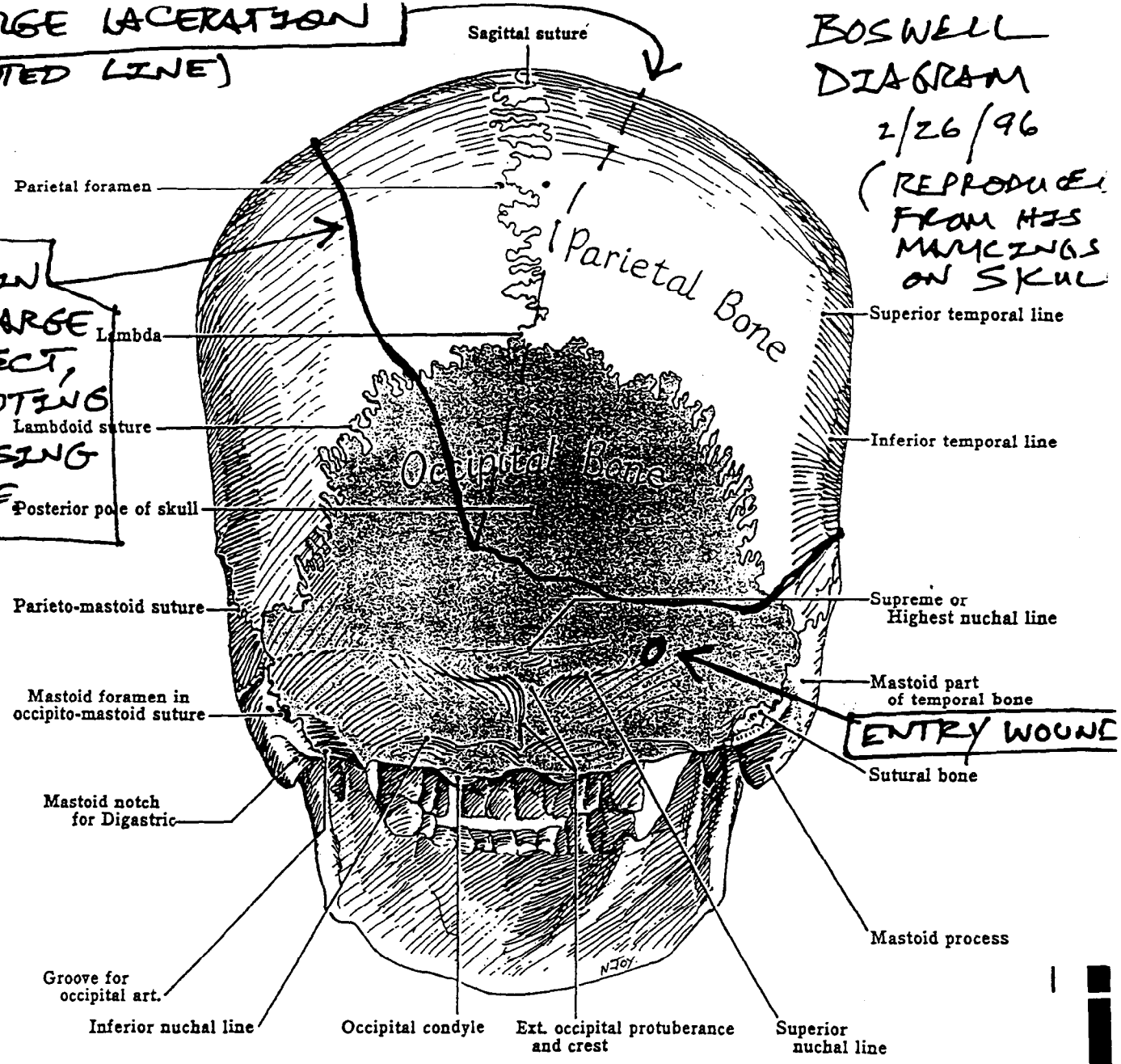


LARGE LACERATION  
(DOTTED LINE)

BOSWELL  
DIAGRAM  
2/26/96

(REPRODUCED  
FROM HIS  
MARKINGS  
ON SKULL)

MARGIN  
OF LARGE  
DEFECT,  
DENOTING  
MISSING  
BONE



7-9 SKULL FROM BEHIND (NORMA OCCIPITALIS)

Observe:

1. The outline is horseshoe-shaped from the tip of one mastoid process over the vertex to the tip of the other.
2. At the base of the skull, the outline is nearly straight from one mastoid process to the other, except where the occipital condyles project downward. On each side, it crosses two grooves (for the origin of the posterior belly of Digastric laterally, and for the occipital artery medially). Between the condyles is the foramen magnum.
3. The surface is convex. Near the center is the lambda. From it a triradiate suture runs: the sagittal (interparietal) upward in the median plane, and the lambdoid (parietooccipital) inferolaterally to the blunt postero-inferior angles of the parietal bones where it bifurcates.
4. On each side are two inconstant foramina for emissary veins and meningeal arteries: parietal and mastoid foramina.
5. Midway between lambda and foramen magnum is the external occipital protuberance or inion. From it the superior nuchal line curves laterally and crosses the lateral aspect of the mastoid, dividing it into a smooth upper and a rough lower part.
6. The surface below the superior nuchal line is the nuchal area for the muscles of the neck or nucha.

1 OF 4  
BPH  
2/27/96

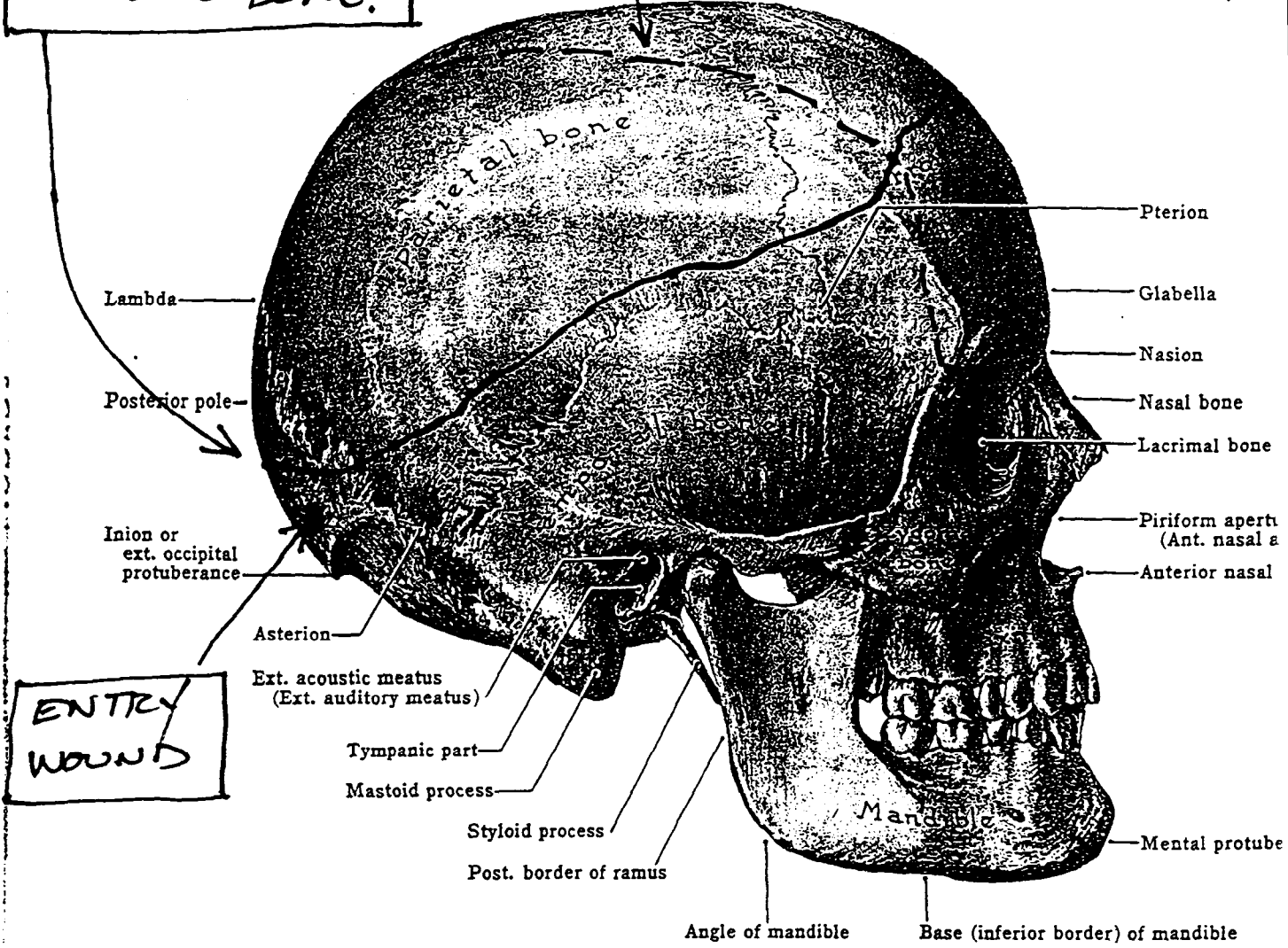
MID 209

DR. BOSWELL EMPHASIZES THIS IS AN APPROXIMATION  
001622

BOSWELL  
DIAGRAM  
2/26/96  
(REPRODUCED  
FROM HIS SKM  
MARKINGS)

LARGE  
LACERATION

MARGIN OF  
LARGE DEFECT,  
DENOTING  
MISSING BONE.



ENTRY  
WOUND

7-6 SKULL, FROM THE SIDE (NORMA LATERALIS)

2 of 4  
JMA  
2/27/96

DR. BOSWELL EMPHASIZES THIS IS  
AN APPROXIMATION.

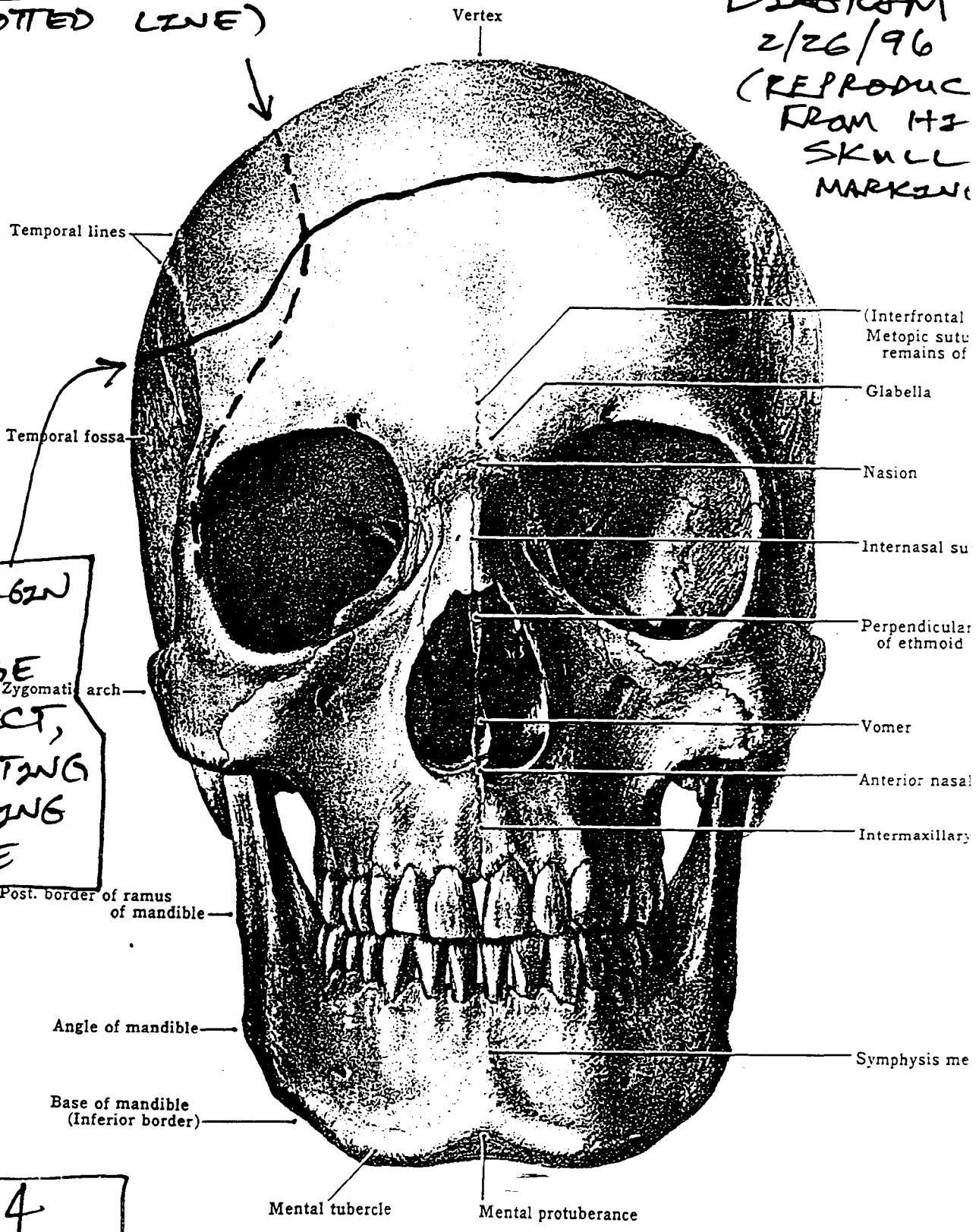
001623

LARGE LACERATION  
(DOTTED LINE)

DIAGRAM  
2/26/96  
(REPRODUCED FROM IHS  
SKULL  
MARKING)

MARGIN  
OF  
LARGE  
DEFECT,  
DENOTING  
MISSING  
BONE

3 of 4  
~~DMM~~  
2/27/96



7-4 SKULL, FRONT VIEW (NORMA FRONTALIS)

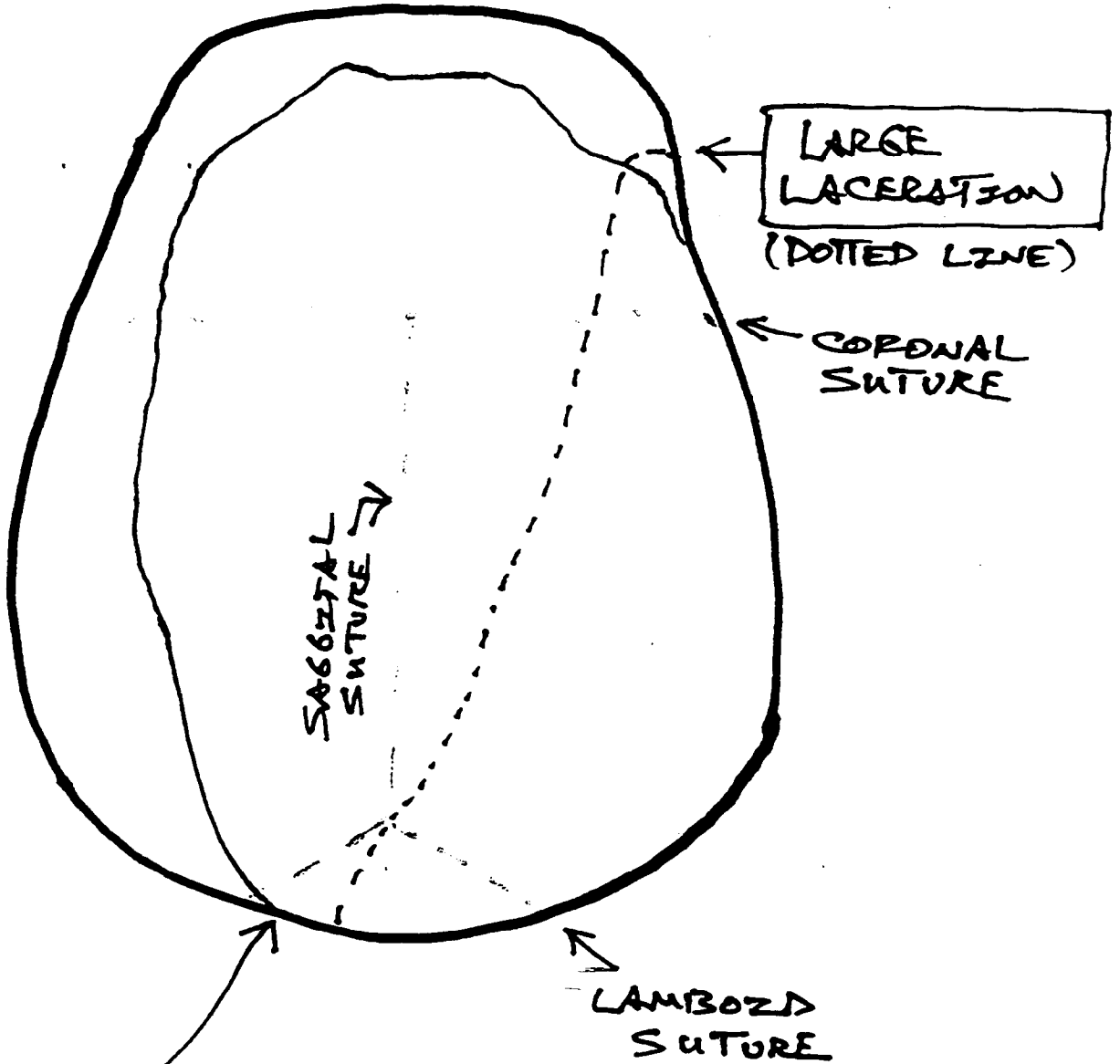
DR. BOSWELL EMPHASIZES THIS AS  
AN APPROXIMATION.

001624

BOSWELL  
DIAGRAM  
2/26/96  
(REPRODUCED  
FROM HIS  
MARKINGS ON  
SKULL)

SUPERIOR VIEW  
OF SKULL

DR. BOSWELL EVIDENCES  
THAT IS AN APPROXIMATION



MARGIN OF  
LARGE DEFECT,  
DENOTING MISSING  
BONE.

001625  
4 of 4  
J.M.W.  
2/27/96